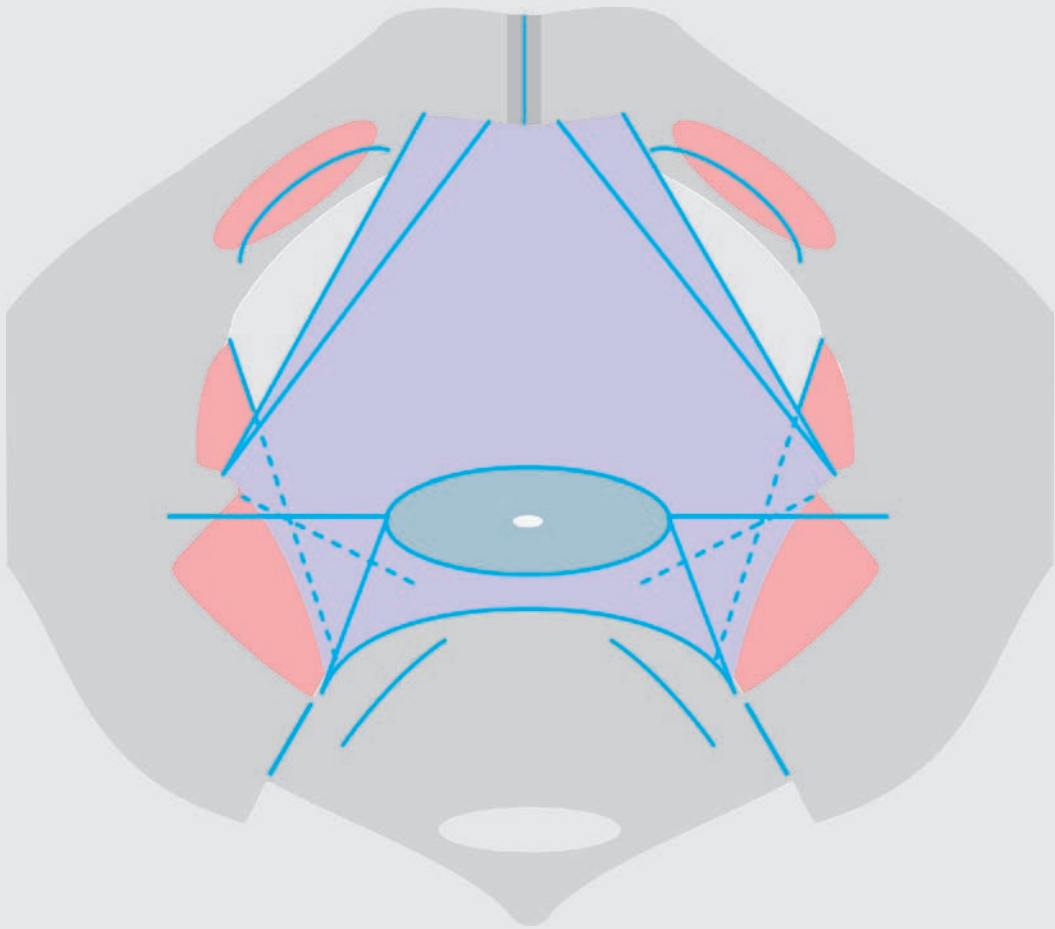


# **obstetric trauma surgery**

## **art and science**

**functional female pelvis anatomy**  
for reconstructive surgery



sponsored and financed by



**ISBN/EAN:** 978-90-79633-63-0

**pages:** 120

**color pages:** 35

**drawings** by the author  
technical assistance by mark

**copyright 2016** by the author

babbar ruga national fistula hospital  
katsina  
nigeria

**obstetric trauma surgery  
art and science**

setting standards by evidence-based practice

**functional pelvis anatomy  
in the female**

**based on**

the conservative/surgical management of the obstetric trauma

as practiced in the

national obstetric trauma project nigeria

kees waaldijk

# obstetric trauma surgery art and science

series of textbooks each with a specific topic

## setting evidence-based standards

this series has been developed for setting evidence-based standards in the training and management of the obstetric trauma in all its forms in the developing as well as in the industrialized world

the name of the series has been changed from obstetric fistula to obstetric trauma surgery since the fistula is only one aspect of the complex obstetric trauma

though a systematic approach is being followed this seems to be a utopia since the material is too extensive and it would take too long

each time a specific topic has been finalized it will be published as a separate entity; with later on an update if needed

then somewhere along the line a comprehensive summary will be produced in order to have a representative overview

the emphasis is placed on the functional anatomy of pelvis, pelvis floor and pelvis organ(s), the female urine and stool continence mechanisms, the mechanism of action and the principles of reconstructive and septic surgery

for training reasons it will follow a step-by-step approach and repetition; together with schematic drawings and photographs

the whole series is based on **kees archives of obstetric trauma** with so far 25,000 reconstructive and conservative procedures in 20,000 patients with a rare "complete" documentation of each procedure and results as to healing and continence by electronic reports, pre/intra/postoperative digital photographs and a comprehensive database as personal experience over a 30-year period from 1984 up till now

as such it is considered to be a full scientific evidence-based report; though it has not followed the "you peer me, i peer you" doctrine

it is also not following the strict protocol of the international scientific journals or the so-called established theories; since only dead fish follow the flow of the river; and strict protocols kill any creativity; the message is not in the format

since it is the life work of the author it is written in his own words and in his own style

# foreword

the meaning and purpose of reconstructive surgery is reconstruction of the functional anatomy ensuring normal physiology; and using autologous structures

anything not in line and conform with the functional anatomy will create a nonphysiologic situation and may work against the patient throughout life

therefore the reconstructive surgeon must have a thorough knowledge of the pelvis anatomy in the female, must be able to understand and visualize the functional anatomy and must have the required qualifications and skills

however, the pelvis anatomy in the female is complicated and it is even more difficult to understand the functional anatomy since there are a multitude of organs and different tracts each with their own characteristics which interact with each other as packed within the confined space of the true pelvis; with hydrostatic and compression pressure

this explains the enormous amount of literature on the pelvis anatomy and functional pelvis anatomy and various theories with confusing and contradicting nomenclature

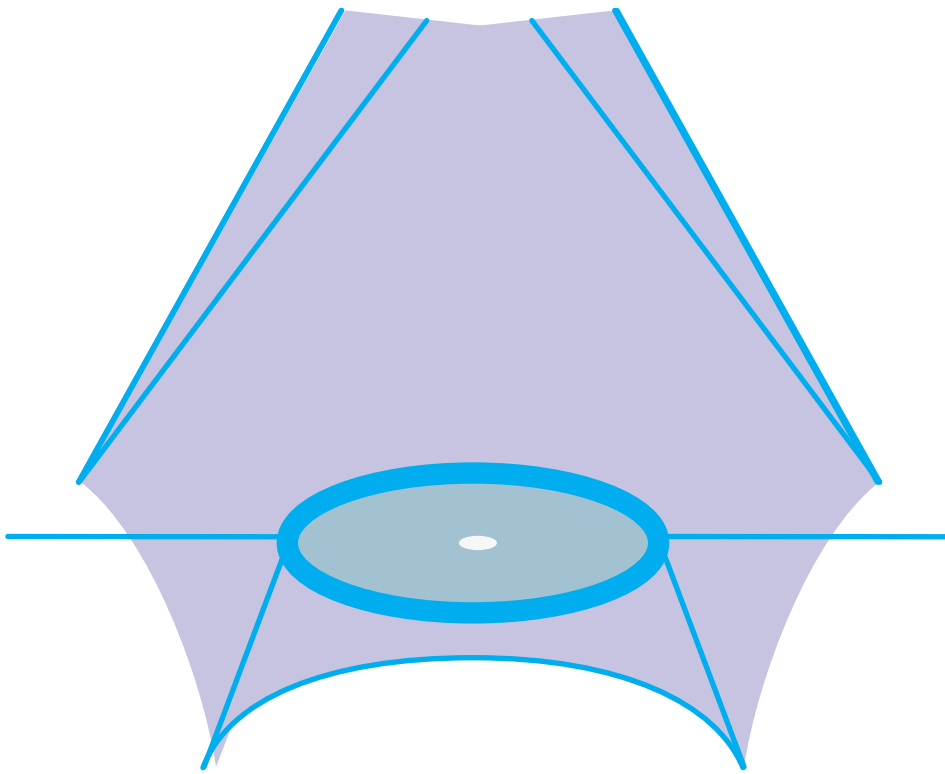
out of the series **obstetric trauma surgery; art and science**, this textbook outlines the pelvis anatomy in the female as compiled from existing anatomic textbooks and the functional pelvis anatomy in the female also compiled from existing anatomic textbooks to which the author added his own very personal view(s) with another concept of the **intrapelvic urogenital diaphragm**

special attention has been paid to the anatomic extent and function of the connective tissue body of pelvis or corpus intrapelvinum as part of the tela urogenitalis; such as stabilizing/securing the organs in their variable anatomic position and supporting the urine, genital and stool continence mechanisms

it represents how one obstetric trauma surgeon is interpreting in the living the anatomic descriptions of the anatomists post mortem in the dead

it is the latest version (and only an outline) of a long and continuing process (which just started as a few memo notes for the author himself) and should serve as an incentive for extensive self-study by the reader

the author hopes this book will contribute to the discussions among other reconstructive pelvic surgeons leading to progress so that our patients will benefit

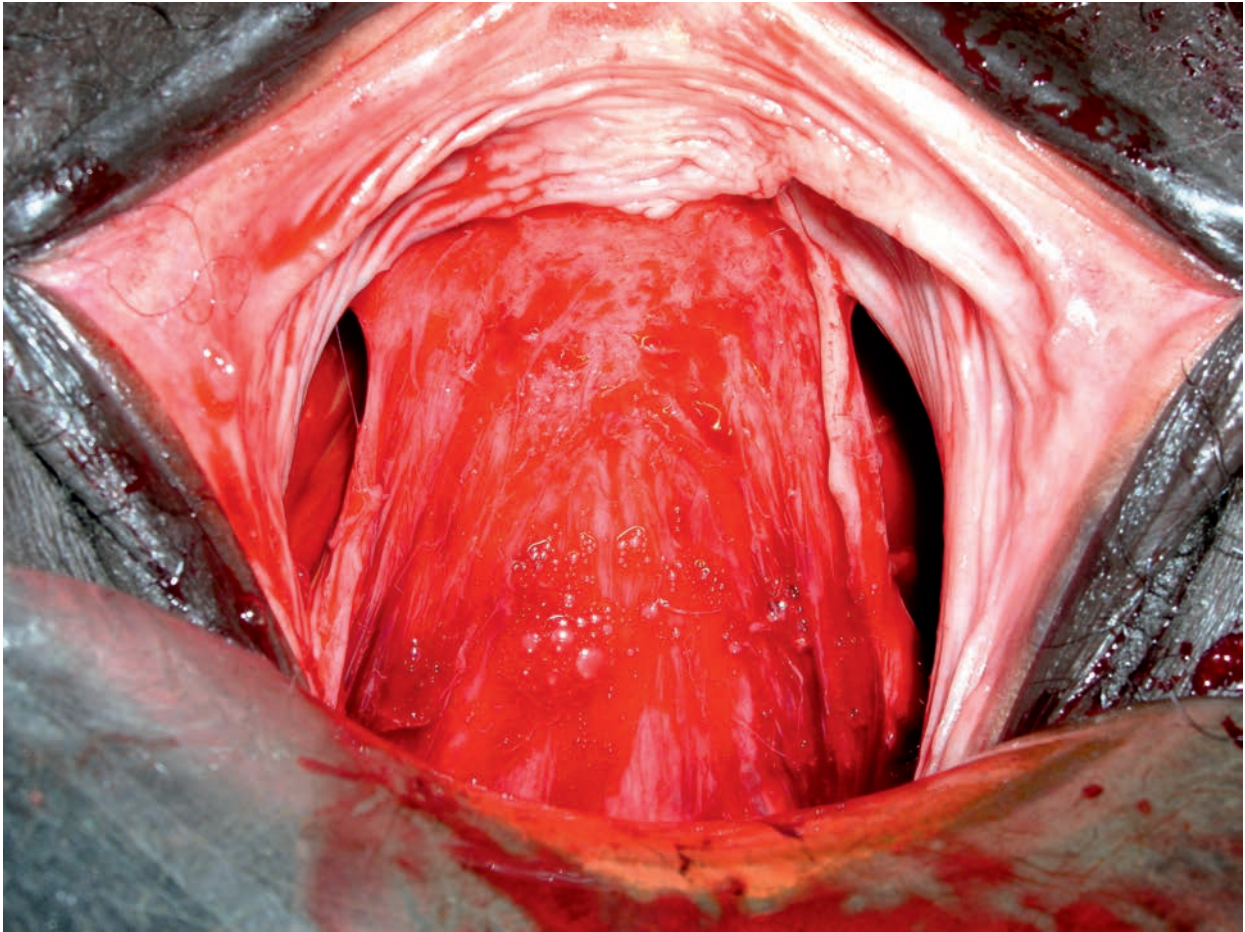


© kees

intrapelvic urogenital diaphragm  
centrum tendineum intrapelvinum

# table of contents

foreword	3
introduction	7
pelvis anatomy	11
functional pelvis anatomy	27
connective tissue body of pelvis	41
intrapelvic urogenital diaphragm	49
urine continence mechanism	59
intraabdominopelvic pressure	67
remarks urine continence mechanism	73
stool continence mechanism	79
levator ani muscles	85
pelvis floor exercises	89
obstetric trauma	91
urine incontinence mechanism	97
urogenital and digestive prolapse	107
essentials	115
reconstructive surgery	117
references	120



© kees

intrapelvic urogenital diaphragm  
pubocervical fascia



# introduction

since the author started with obstetric trauma surgery in 1983 he tried to get a proper view of the complicated pelvis (floor) anatomy and an understanding of the physiology especially of the urine and stool continence/closing mechanisms since

at an early stage he started to realize that he should attend to the real obstetric trauma by reconstruction of the functional pelvis anatomy with closure of the fistula during the surgical process instead of concentrating only upon the fistula and leaving the rest

it took quite some time to master the anatomy by hard study, far longer to have a three-dimensional view and very long to visualize everything in the upright and also other positions; he is still in the process of understanding the functional relations between all these structures especially with regards to the urine and stool continence mechanisms in the female and the development of urine intrinsic stress incontinence and urogenital and digestive prolapse due to hydrostatic pressure, to obstetric trauma and/or to ageing processes

for the last 30 years there has been hardly a day the author was not actively involved in clinical research; every day and every operation the author is still in a learning process finding new clues and (non)confirming theories and operation technique principles; actually, the obstetric trauma never leaves his system and is stuck there, consciously and unconsciously

of great help was the fact that the author is in the lucky possession of a bony female pelvis so he can check and visualize the anatomic descriptions in the textbooks and

the fact that he started with the immediate surgical management of the obstetric trauma and found the real fresh defects before they had time to heal

right from the beginning he followed the basic surgical principles which gave good results in closure of the obstetric fistula and in obtaining continence

however, with the purpose of achieving optimal results he changed his opinion and his surgical management many times according to his continuously increasing insight and as guided by evidence-based results always pursuing the same goal:

## reconstruction of the functional anatomy ensuring physiology

though he found the right path rather early by analyzing the findings and results he is still in the process of perfecting his anatomic knowledge, his insight into the functional pelvis anatomy, his operation technique principles and his surgical skills

however, how hard he studied he failed to comprehend the various theories since there was a discrepancy between what he saw/found during his extensive obstetric trauma reconstructive surgery and all these theories

the anatomy and functional anatomy do not change, except for under evolutionary impulses; only our interpretation; but it seems **another concept** is needed for a comprehensive understanding of the functional pelvis anatomy in the female

in this book the author presents his very personal view of the functional pelvis anatomy in the female in order to introduce

the **intrapelvic urogenital diaphragm** in the female as a dynamic and the most important structure for support of the urine and genital continence mechanisms and for support of the urogenital organs in their variable anatomic position

this is only the latest and a condensed version of what started as a few memo notes for the author himself and his trainees in a still ever-continuing process

and time will tell if this concept is right or wrong

the purpose of this book is to provide the basic knowledge  
in order to proceed with further books dealing with  
the complex obstetric trauma in detail  
and its surgical management

and

to claim credit as a scientific study

the author

may 2016

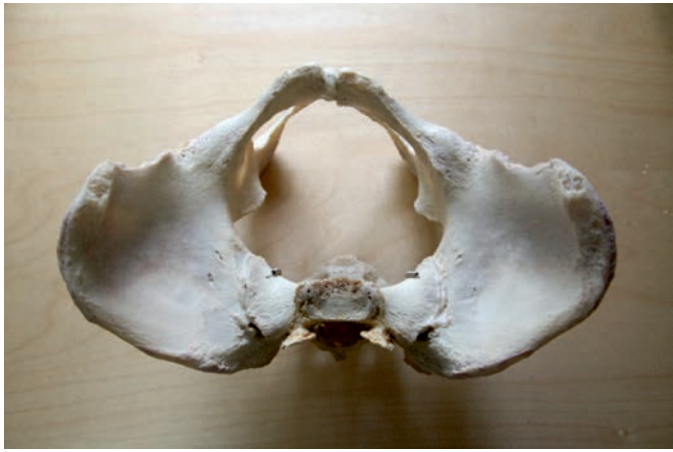

fig 1 pelvis



fig 2 pelvis © kees



fig 3 symphysis pubis © kees

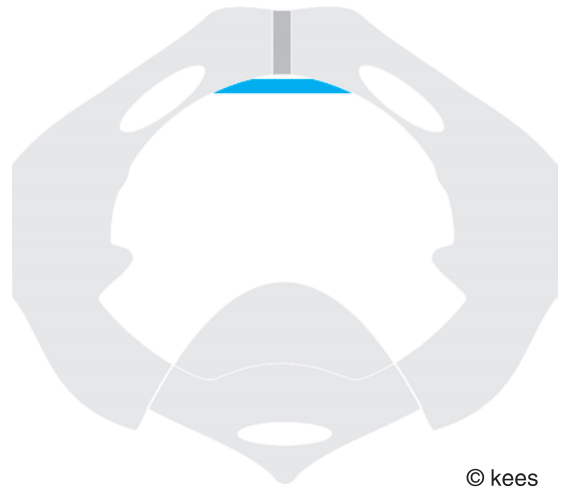


fig 4 arcuate ligament © kees



fig 5 sacroiliac ligaments © kees

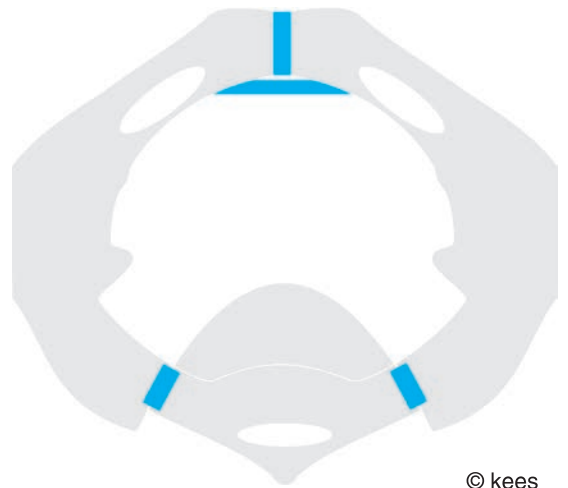


fig 6 stabilizing pelvis ligaments © kees



© kees

fig 7

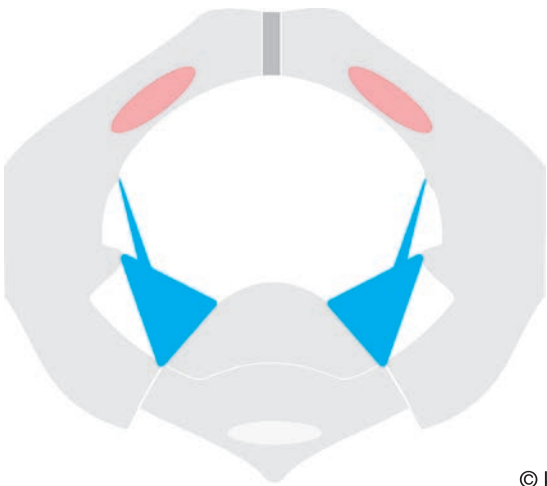sacrospinous ligament



© kees

fig 8

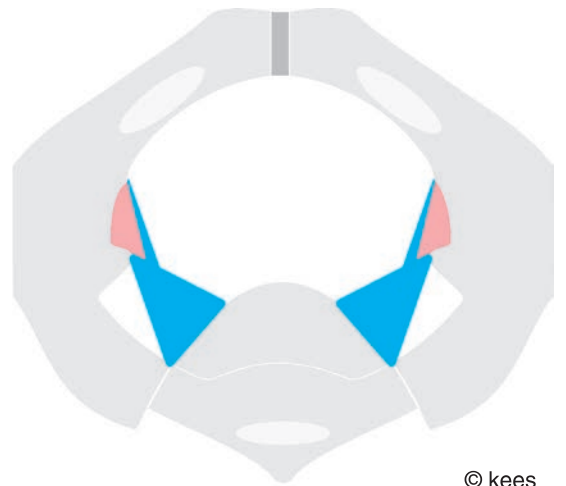
sacrotuberous ligament



© kees

fig 9

sacrotuberous ligament  
sacrospinous ligament  
obturator foramen



© kees

fig 10

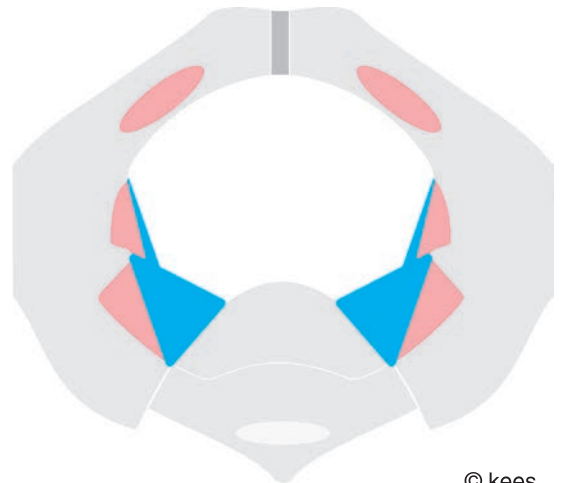
greater sciatic foramen



© kees

fig 11

lesser sciatic foramen



© kees

fig 12

pelvis foramina

# anatomy of female pelvis

based on existing anatomic textbooks

## introduction

mastering the pelvis anatomy is not an easy task since the anatomy is complicated but it is the first step for any surgeon in whatever field since reconstruction of the functional anatomy will ensure normal physiology

here only a short comprehensive outline is given as a start/incentive to more extensive self-study; it is based on existing anatomic textbooks with some personal comments

only the lesser or true pelvis is considered within the context of the abdominopelvic cavity

## bony pelvis

consists of 3 paired bones and 2 single bones connected to each other via joints and ligaments

paired **pubis** bones

with body and superior/inferior rami as joined in the midline by the

**symphysis pubis**

paired **ischium** bones

paired **ilium** bones

single **sacrum** bone

single **coccyx** bone

the 3 paired bones pubis, ilium and ischium are fused together by ossification

it forms a cavity for the distal outlet end organs of the urinary tract, the genital tract and the digestive tract; normally in a continent way

it is also part of the musculoskeletal locomotion system with insertions for abdominal muscles and hip muscles

## ligaments stabilizing bony pelvis

### **symphysis cartilage**

joining pubis bones anteriorly in the median; whilst whole complex also referred to as symphysis

### **arcuate ligament**

between inferior pubis bones just caudad from symphysis cartilage

### **sacroiliac ligaments**, dorsal and ventral

between ilium bones and sacrum

### **sacroteruberous ligaments**

broad base from dorsal posterior iliac spine, dorsal lateral parts of sacrum, upper lateral part of coccyx to medial ischial tuberosity

### **sacrospinous ligaments**

in front of sacrotuberous ligaments, triangular in shape with a broad base from lateral lower parts of sacrum, lateral upper part of coccyx to ischial spine; (ischio)coccygeus muscles fused with its lower pelvic aspects

## pelvis divided into greater pelvis and lesser or true pelvis

for anatomic and functional reasons the pelvis is divided into a greater and a lesser or true pelvis as divided by the linea terminalis which also forms the inlet opening into the true pelvis

### greater pelvis

consists of bones posterobilaterally and abdominal muscles anterobilaterally and forms the lower part of the abdominal cavity and is separated by the linea terminalis from the lesser or true pelvis, the topic of this book

though normally occupied by the intraperitoneal organs, also intrapelvic organs may protrude into it

### true pelvis

consists of a combination of bones, ligaments and muscles lining the bones or filling up the gaps in between bones with a funnel-like shape which is short and straight anteriorly (symphysis) and longer and concave-curved posteriorly (sacrum promontory to tip of coccyx bone)

though normally occupied by the intrapelvic organs, also some intraperitoneal organs like small bowel and sigmoid colon may protrude into it

there is a pelvis inlet into the true pelvis and a pelvis outlet and several other bilateral openings like obturator foramen and (greater and lesser) sciatic foramina

### functional pelvis cavity

the functional pelvis cavity is the space in between the **parietal pelvis fascia** and the **parietal peritoneum** connected to each other by the **tela urogenitalis** into which the pelvis organs with their arterial blood supply, venous drainage, lymphatic drainage and innervation are embedded; see next chapter

## pelvis inlet = apertura pelvis superior

round or oval shape as the upper (bony) ring in one plane through anteriorly superior symphysis edge, laterally upper edge of superior pubis bones and linea arcuata and posteriorly the promontory; the bony ring is interrupted anteriorly by the symphysis cartilage joint and posterobilaterally by the sacroiliac joints

inclination 55-60° with horizontal from superior symphysis edge anteriorly to promontory posteriorly in the upright position

## pelvis outlet = apertura pelvis inferior surface some 75-80 sq cm

diamond shape from inferior symphysis edge along ischiopubic rami to (bi)lateral ischial tuberosities to tip of coccyx bone; the anterior triangle for the urogenital tract between symphysis and tuberosities in one plane and the posterior triangle for the digestive tract between tuberosities and tip of coccyx in another one plane

however there still remain some bony gaps posterobilaterally which are filled up by the levator ani muscles, sacrospinous and sacrotuberous ligaments and piriformis muscles

anterior triangle in one plane with -10 to -15° inclination as to horizontal from symphysis to ischial tuberosities

posterior triangle in one plane with 65 to 70° inclination as to horizontal from ischial tuberosities to tip of coccyx

the direct inclination between inferior symphysis and tip of coccyx is 10-15°

anteroposterior diameter recta from inferior symphysis to tip of coccyx is 9-9.5 cm; can enlarge to 11 cm during childbirth; with transverse intertuberosity diameter of 10-11 cm

## pelvis floor

the pelvis outlet is more or less closed off by the pelvis floor structures; however with 3 openings for urethra, vagina and rectum; and consists of

### **pelvis “diaphragm”**

the superior “antero”lateroposterior layer of the pelvis floor; as formed by the levator ani muscles with (ischio)coccygeus muscles/sacrospinous ligaments as a U sling around the anorectum and in total like a shallow bowl with its deepest point at the anus

with an anterior sagittal median hernia-prone opening within the diaphragm of 7-8 x 3.5-4 cm (some 25-30 sq cm) between the two puborectalis ledges

### **perineum outlet diaphragm**

the inferior layer of the pelvis floor with perineal body as its center; formed by perineal membrane, external sphincter ani muscle, perineal body, transversus perinei muscles, bulbospongiosus muscles, ischiocavernosus muscles and anococcygeal ligament; and bilateral crura of clitoris

the outgoing distal end organs of the urinary tract, genital tract and digestive tract with their continence mechanisms are firmly anchored into the pierced thru punched out openings in the outlet diaphragm and constitute part of it

as such the organs cannot prolapse directly to the outside but only by kind of intussusception dragging the vagina (wall) with them

inclination of 10-15° as to horizontal from inferior symphysis edge anteriorly to tip of coccyx posteriorly

the pelvis floor is covered on the outside by the pudendal organs: **clitoris, vestibule** and **labia minora/majora**

## pelvis foramina

### **obturator foramen**

between superior pubis, inferior pubis and ischium bones; it is closed by the obturator membrane with a small opening as a canal for blood and nerve supply to the obturator externus muscle

the sacrospinous ligament divides the space between the ischial notch/spine and sacrum/coccyx into foramina with the sacrotuberous ligament as boundary:

### **greater sciatic foramen**

thru which piriformis muscle, superior and inferior gluteal vessels and nerves, internal pudendal vessels and nerve, sciatic nerve caudad from piriformis muscle, posterior femoral nerve and nerves to obturator and quadratus femoris muscles; is the cephalad = superior foramen

### **lesser sciatic foramen**

thru which internal obturator muscle tendon, nerve to internal obturator muscle, internal pudendal vessels and pudendal nerve; is the caudad = inferior foramen

## pelvis muscles

there are 2 intrapelvic muscles which function as exo-rotators/abductors of the hip

### **obturator internus muscle**

originates from pelvic surface of obturator membrane and pubic and ischial margins of obturator foramen with its tendon thru the lesser sciatic foramen and inserts into medial surface of trochanter major

### **piriformis muscle**

originates from pelvic surface of sacrum and ilium, passes thru greater sciatic foramen and inserts into upper border of trochanter major

and four extrapelvic muscles as exo-rotators of the hip: obturator externus muscle, gemellus superior muscle, gemellus inferior muscle and quadratus femoris muscle



then there are muscles which constitute the “anterior” and bilateroposterior part of the superior layer of pelvis floor as shallow-bowl-shape “pelvis diaphragm” with anus as most caudad point

**levator ani muscles**

originating from pubis body and atlam and inferior edge of sacrospinous ligament and inserting into levator plate, coccyx and anococcygeal ligament; actually one flat muscle but normally divided into different parts

**pubococcygeus muscles**

from pubis body and atlam to levator plate and anococcygeal ligament

**puborectalis muscles**

medial part of pubococcygeus muscles fusing behind rectum and pulling it anteriorly

**iliococcygeus muscles**

from atlam to levator plate, coccyx and anococcygeal ligament

**(ischio)coccygeus muscles**

from ischium and inferior edge of sacrospinous ligament to sacrum and coccyx

and muscles which form the anterior part of the perineum outlet diaphragm as the inferior layer of pelvis floor

**compressor urethrae muscle**

in the deep perineal space between perineal membrane and levator ani muscles but not mentioned in older textbooks

**urethrovaginalis muscle**

in the deep perineal space between perineal membrane and levator ani muscles but not mentioned in older textbooks

**bulbospongiosus muscles**

in the superficial perineal space from symphysis and clitoris and radiating into perineal body; closes the vagina introitus and stabilizes the (anterior) anus

**ischiocavernosus muscles**

in the superficial perineal space from ischial tuberosity into clitoris

**transversus perinei muscles**

from ischial tuberosity and radiating into perineal body for stabilization of (anterior) anus

## pelvis connective tissue

the organs of the pelvis together with their arterial blood supply, venous drainage, lymphatic drainage and innervation are embedded into and suspended/connected to the pelvis wall and to each other via a complicated system of connective tissue, called connective tissue body of pelvis = corpus intrapelvinum; see special chapter

it consists of a cohesive mixture of collagen for strength, elastin for passive elasticity and plasticity and smooth muscle tissue for active tonus and relaxation; under control of the autonomic nervous system

in a loose, dense or condensed form and may be highly specialized according to the needs as fascia, ligament or plica such as

**parietal pelvis fascia**

the general layer that lines the inner aspects of the pelvis cavity wall

**visceral fascia**

from tela urogenitalis for packing/encapsulating the organs as fascia of the organs and for ensheathing the blood vessels, lymphatic vessels and nerves

**obturator membrane**

the obturator membrane closes the obturator foramen and forms the origin of the obturator externus muscle on the outside and the origin of the obturator internus muscle on the inside

**obturator fascia**

fascia covering obturator internus muscle

**arcus tendineus of levator ani muscle = atlam**

as line of fusion from 1.5-2 cm laterally from midline from posterior pubis bone body over obturator internus muscle fascia to ischial spine; as origin of levator ani muscle

**levator ani fascia**

fascia covering levator ani muscle

**arcus tendineus fasciae = atf**

as line of fusion bilaterally from posterior pubis bone body 0.5-1 cm from midline pubis symphysis to ischial spine; as anterolateral attachment of intrapelvic urogenital diaphragm to pelvis wall

it is connected to the obturator fascia and to the arcus tendineus of levator ani muscle via a narrow triangular fascia sheath

inclination of 115-120° as to horizontal from anterior to posterior in upright position

**pubocervical fascia = vesicovaginal fascia**

in between the posterior bladder wall and anterior vagina wall as part of the intrapelvic urogenital diaphragm; see special chapter

**arcus tendineus of rectovaginal fascia = atrf**

as line of fusion from lateral side of perineal body over levator ani fascia to ischial spine and fuses with the posterior part of the arcus tendineus fasciae

**rectovaginal fascia = prerectal fascia**

in between the posterior vagina wall and anterior rectum wall and fixed anteriorly to the perineal body, (bi)laterally to arcus tendineus of the rectovaginal fascia and posteriorly to the cervix and the sacrouterine ligaments

**vesicoumbilical fascia**

in between bilateral vesicoumbilical ligaments from bladder to umbilicus

**perineum membrane**

semicircular from symphysis and arcuate ligament in between both ischiopubic rami of pubis bones up (in)to perineal body and transversus perinei muscles with small opening for the urethra and wide opening for the vagina

this membrane separates the deep perineal space, between the membrane and levator ani muscle fascia, from the superficial perineal space, between the membrane and the subcutaneous fascia

**perineal body**

wedge-like connective tissue structure in between the vagina and the anus; into which the perineum membrane, bulbospongiosus muscles and transversus perinei muscles radiate; as centrum tendineum perinei

it stabilizes the (anterior) anus in its anatomic position since it is firmly attached to the external sphincter ani muscle

**medial vesicoumbilical ligament**

obliterated urachus

from median bladder to umbilicus

restricting the upward movement of the bladder

**(bi)lateral vesicoumbilical ligaments**

obliterated umbilical arteries

from bilateral internal iliac artery to umbilicus

restricting the upward and sideward movement of the bladder

**pubovesical ligaments = pubovesical muscles**

condensation of pubocervical fascia

stabilizing the posterior bladder neck

**posterior pubourethral ligaments = pubourethral muscles**

condensation of pubocervical fascia as anterior attachment to pubis bones

stabilizing the posterior proximal/mid urethra wall

**anterior and intermediate pubourethral ligaments**

condensation of perineum outlet diaphragm

anchoring distal urethra and external urethra opening

**cardinal ligaments**

from ilium/ischium bones to (bi)lateral cervix in a frontal plane cephalad to the ischial spines

suspending/connecting the cervix and intrapelvic urogenital diaphragm bilaterally to the pelvis wall

**sacrouterine ligaments = rectouterinus muscles**

from cervix to rectum and sacrum

attached to (ischio)coccygeus fascia and piriformis fascia via fascia sheath

**pelvis organs**

the organs with their arterial blood supply, venous drainage, lymphatic drainage and innervation are embedded into and connected to the pelvis wall and each other by the corpus intrapelvinum as part of the tela urogenitalis

**ureter**

though the ureter is completely embedded into the tela subserosa it can be divided into a proximal retroperitoneal abdominal part and a distal subperitoneal pelvic part

suspended/connected to lateral pelvis wall by parametrium and paracystium as part of tela urogenitalis

blood supply  
small vessels from all arteries it crosses  
innervation  
by autonomic nervous system

### **bladder = vesica = cystium**

suspended/connected anteriorly onto the abdominal wall by the medial and lateral vesicoureteral ligaments and to the symphysis by loose connective tissue and thin fluid film and by the pubovesical ligaments and to the lateral pelvic wall by the paracystium; all as part of the tela urogenitalis

blood supply

upper part: usually by 2 or 3 superior vesical arteries from upper part of umbilical artery  
lower part/neck: by inferior vesical artery and neck also by vaginal arteries

innervation

many nerve fibers from vesical (and prostatic) plexus as forward extension of inferior hypogastric plexuses from autonomic nervous system

### **female urethra**

suspended/connected to the symphysis by loose connective tissue and thin fluid film and by the pubourethral ligaments as part of the intrapelvic urogenital diaphragm and distally anchored into perineum outlet diaphragm

blood supply

upper part: inferior vesical artery

middle part: inferior vesical artery and uterine artery

lower part: internal pudendal artery

innervation

upper part: vesical and uterovaginal plexuses of autonomic nervous system

lower part: pudendal nerve

### **uterus, tubes and ovaries**

though they are situated intraperitoneally they belong to the pelvic organs

they are suspended/connected to the lateral pelvic wall by the parametrium as part of the tela urogenitalis

blood supply

uterine artery

innervation

autonomic sympathetic and parasympathetic system

### **cervix**

entering thru the apical pubocervical fascia and proximal anterior vaginal wall; stabilized in its anatomic position by the intrapelvic urogenital diaphragm and cardinal ligaments; it is also the centrum tendineum intrapelvinum

blood supply

branches of uterine artery

innervation

autonomic sympathetic and parasympathetic system

### **vagina = colpos**

suspended/connected to the (bi)lateral pelvic walls by the paracolpium as part of the tela urogenitalis and distally anchored into perineum outlet diaphragm

the anterior vaginal wall is loosely adherent to pubocervical fascia and as such indirectly fixed to the pelvic wall

the posterior vagina wall is adherent to prerectal fascia and perineal body and as such indirectly fixed to the pelvis wall

blood supply

upper part: branches of uterine artery

vaginal artery as 2 or 3 branches from internal iliac artery may anastomose in median plane to form longitudinal trunks as anterior and posterior azygos arteries of vagina

lower part: branches from artery of bulb of vestibule

innervation

by uterovaginal plexus of autonomic nervous system except for its lowermost part by pudendal nerve

therefore there is little sensation except for its lowermost part

### **rectum = proctium**

is adherent to the sacrum and rests upon the levator ani plate, anococcygeal ligament, and coccyx and connected (bi)laterally to the pelvis wall by the paraproctium as part of the tela urogenitalis

reflection of peritoneum at anterior rectum at 5-6 cm from anus; distal part of rectum not covered by peritoneum

blood supply

most important unpaired superior rectal artery as continuation of inferior mesenteric artery

then paired middle rectal artery, inferior rectal artery and median sacral artery

extensive anastomosis between the arteries; so if inferior mesenteric artery ligated, the middle and inferior rectal artery can supply the entire rectum

innervation

autonomous sympathetic and parasympathetic system: from pelvic plexus and from mesenteric plexus

### **anorectum with sphincter complex**

the anorectum is fixed in its position by anococcygeal ligament, levator plate, pubococcygeus muscles, puborectalis muscles, perineal body (centrum tendineum perinei), bulbospongiosus muscles and transversus perinei muscles; and it is anchored into the perineum outlet diaphragm

blood supply

unpaired superior hemorrhoidal artery (from superior rectal artery) and paired middle hemorrhoidal artery = middle rectal artery and paired inferior hemorrhoidal artery = inferior rectal artery (both from internal pudendal artery)

innervation

inferior rectal nerve from pudendal nerve also for external sphincter whilst

the internal sphincter is under autonomic parasympathetic and sympathetic control

## **pudendal organs**

### **introitus or vulva or vestibule**

#### **labia majora/minora**

blood supply

anterior labial branches from external pudendal artery and posterior labial branches from internal pudendal artery

innervation

anterior labial nerve (ilioinguinal nerve) and posterior labial nerve from pudendal nerve

## **clitoris**

blood supply  
clitoridal artery from internal pudendal artery  
innervation  
pudendal nerve and ilioinguinal nerve

## **pelvis blood supply**

### **internal iliac (hypogastric) artery**

from common iliac artery  
supplies most of the pelvis

### **internal pudendal artery**

from internal iliac artery  
inferior rectal artery  
posterior scrotal (labial) branches  
perineal artery  
artery of penis bulb  
artery of bulb of vestibule  
urethral artery  
deep artery of penis or clitoris  
dorsal artery of penis or clitoris

### **visceral branches from internal iliac artery**

umbilical artery  
superior vesical artery  
ductus deferens artery homologous to uterine artery  
inferior vesical artery

### **uterine artery**

from internal iliac artery

### **vaginal artery**

from internal iliac artery; sometimes in combination with uterine artery

### **superior rectal artery; unpaired**

as continuation of **inferior mesenteric artery**: most important

### **middle rectal artery**

either directly from internal iliac artery or from beginning of pudendal artery  
with collaterals to

### **inferior rectal artery**

from internal pudendal artery

## **pelvis nerves**

### **nerve supply = innervation**

from the sacral and coccygeal spinal nerves and from the pelvic part of the autonomic nervous system from sympathetic trunk and aortic plexus

### **sacral plexus (L4 to S5)**

12 named branches:

7 distributed to the buttock and lower limb:

superior gluteal nerve (L5 to S1)

inferior gluteal nerve (L5 to S2)

nerve to quadratus femoris muscle (L4 to S1)

nerve to obturator internus muscle (L5 to S2)

posterior femoral cutaneous nerve (S1 to S3)

perforating cutaneous (inferior medial clunial) nerve (S2, S3)

sciatic nerve (L4 to S3), largest nerve in the body, leaves pelvis thru greater sciatic foramen below the piriformis muscle; the two parts may leave separately, peroneal portion pierces the piriformis or even above piriformis and the tibial portion passes below it and the two parts remain separate throughout their course

5 distributed to the pelvis

nerve to piriformis (S1, S2)

nerves to levator ani and coccygeus (S3, S4)

nerve to sphincter ani externus (perineal branch of S4)

pelvic splanchnic nerves (S (2), 3, 4, (5))

### **pudendal nerve (S2, 3, 4)**

thru greater sciatic foramen below piriformis muscle and crosses the back of the ischial spine and supplies as well sphincter ani externus muscle and skin around anus and anus mucosa up to pectinate line.

## **some important facts**

### **upright position**

the anterior superior iliac spines and pubis bone tubercles are in the same frontal plane in the upright position

the promontory, ischial spines, cervix, ischial tuberosities and perineal body are in the same frontal plane in the upright position

### **axis symphysis pubis**

30-45° as to horizontal/ground from caudad=inferior to cephalad=superior in upright position; symphysis is 5-6 cm broad

### **axis pubocervical fascia**

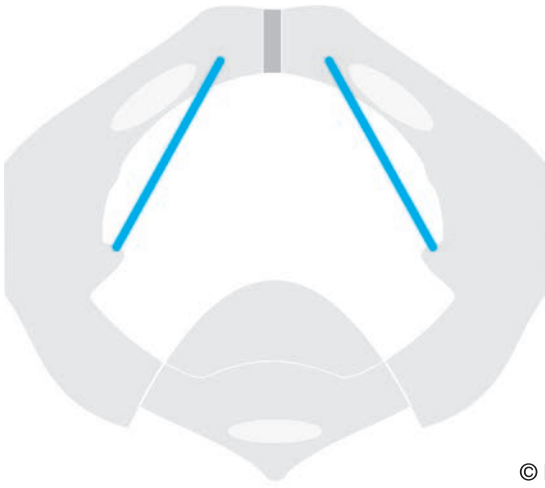25-30° as to horizontal/ground from symphysis to sacrum in upright position

### **angle between arcus tendineus fasciae and symphysis**

this is in the range of 110-125°

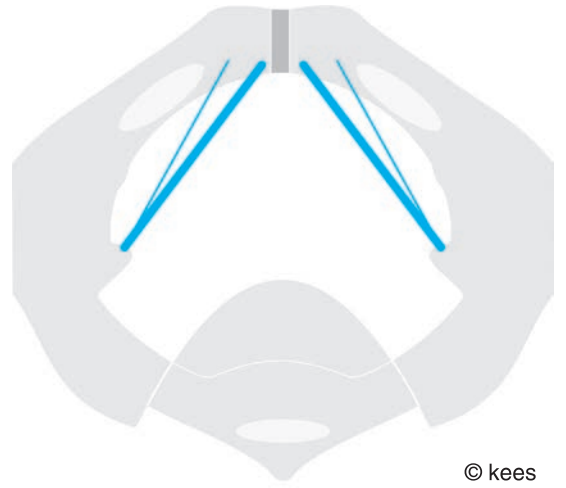
## **discussion**

though this is a condensate from the existing textbooks the author added some things and phrased some things in a different way



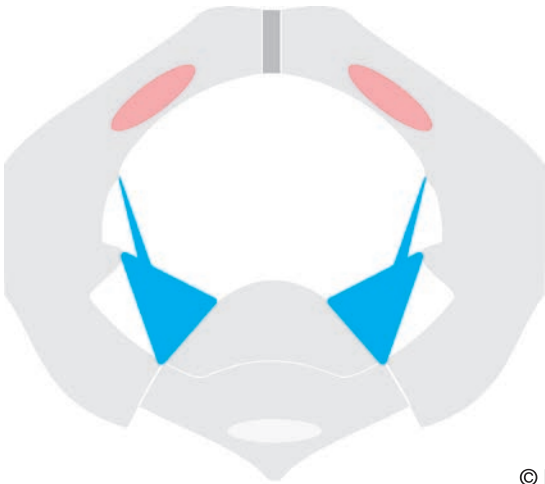© kees

fig 13 arcus tendineus levator ani muscle  
atlam



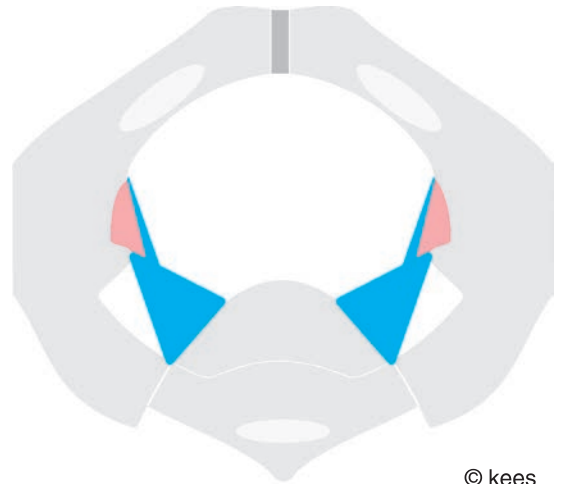
© kees

fig 14 arcus tendineus fasciae  
atf



© kees

fig 15 atf + atlam



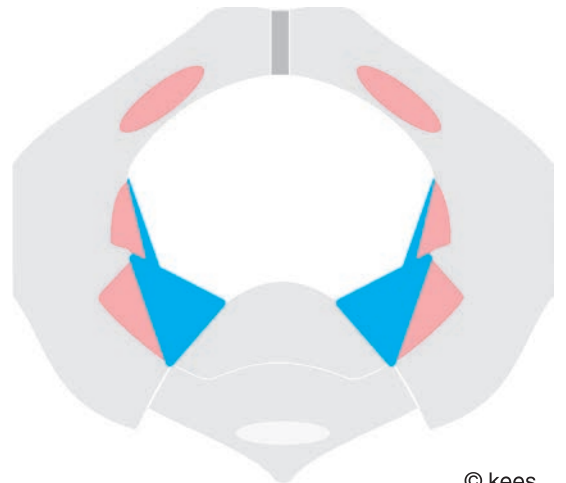
© kees

fig 16 origin pubococcygeus muscle  
as part of levator ani



© kees

fig 17 origin iliococcygeus muscle  
as part of levator ani



© kees

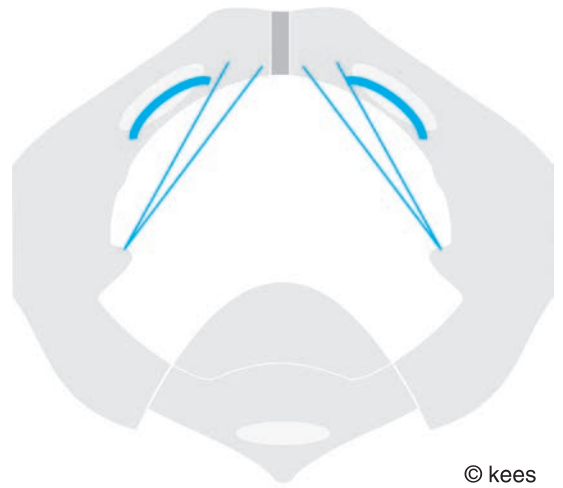
fig 18 origin (ischio)coccygeus muscle  
as part of levator ani





© kees

fig 19 origin obturator internus muscle



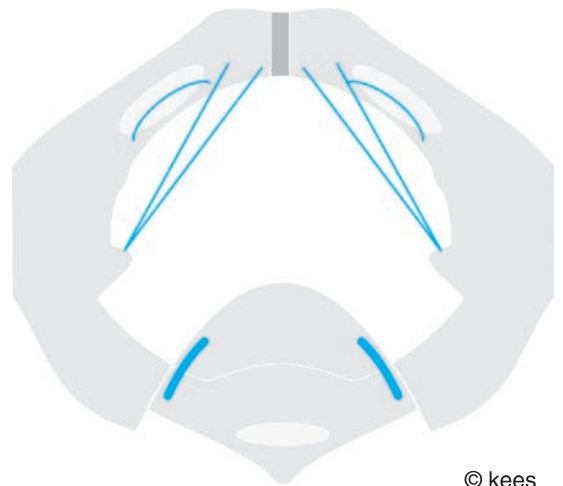
© kees

fig 20 origin obturator internus muscle



© kees

fig 21 origin piriformis muscle



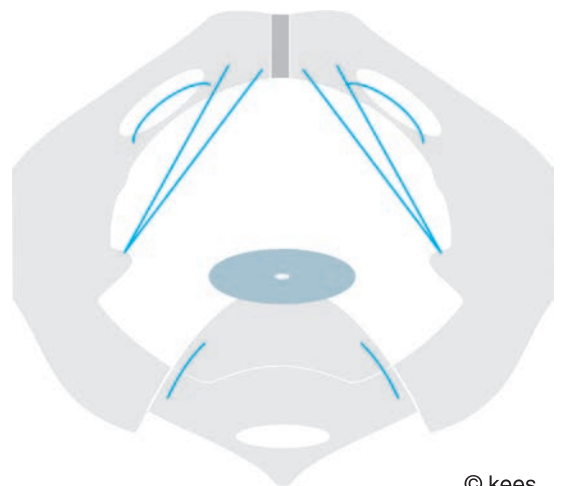
© kees

fig 22 origin piriformis muscle



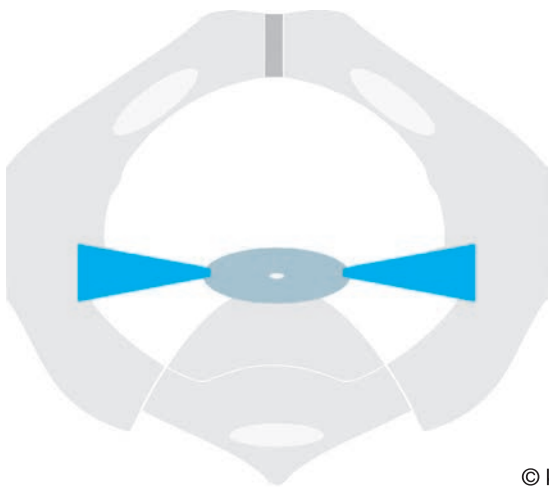© kees

fig 23 cervix



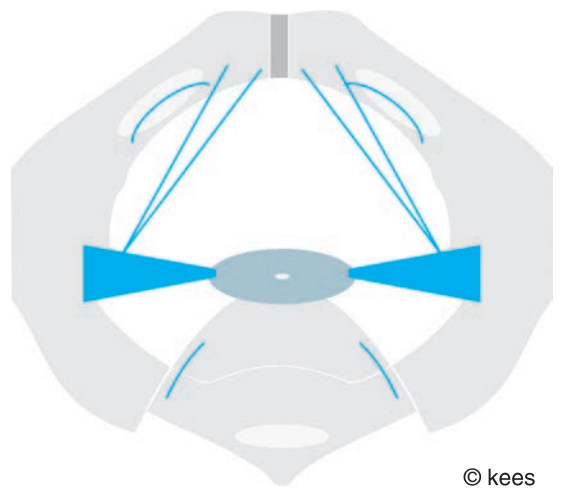
© kees

fig 24 cervix



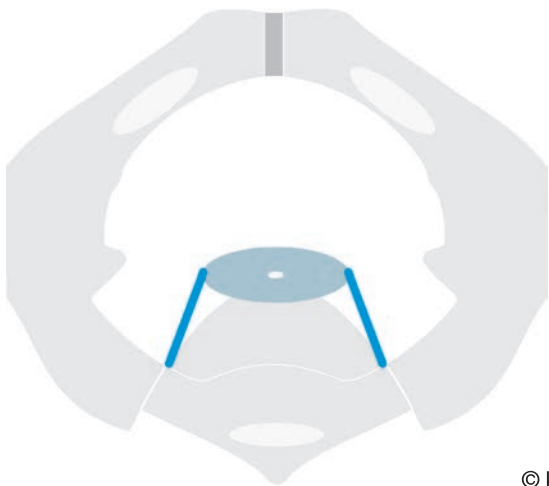© kees

fig 25 cardinal ligaments



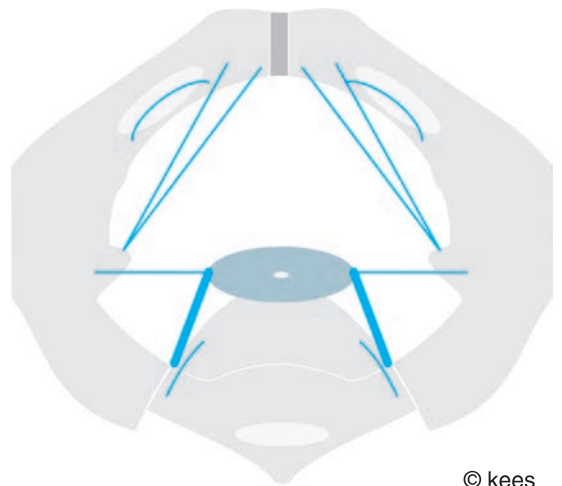
© kees

fig 26 cervix + cardinal ligaments



© kees

fig 27 sacrouterine ligaments



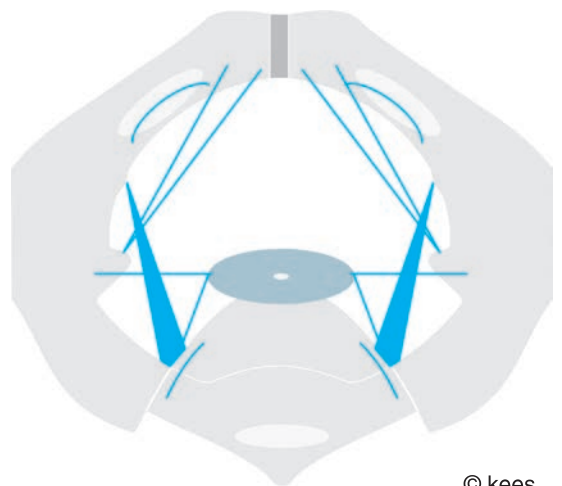
© kees

fig 28 cervix + sul



© kees

fig 29 sacrotuberous ligaments



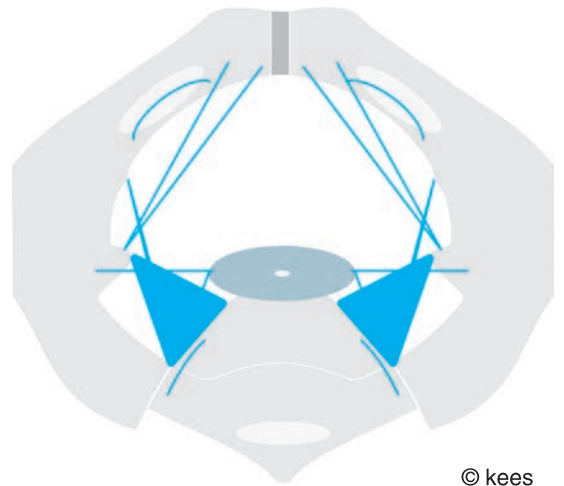
© kees

fig 30 sacrotuberous ligaments



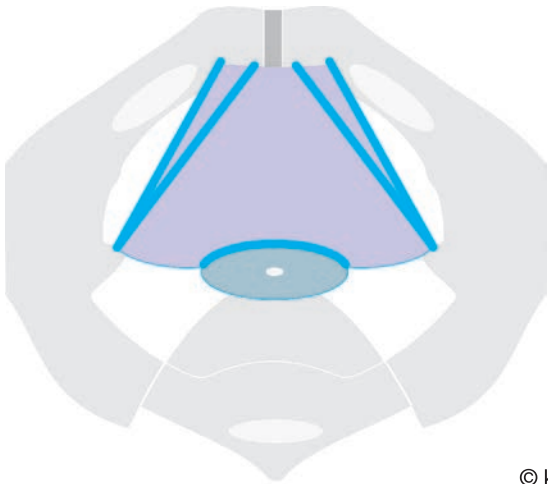
© kees

fig 31 sacrospinous ligaments



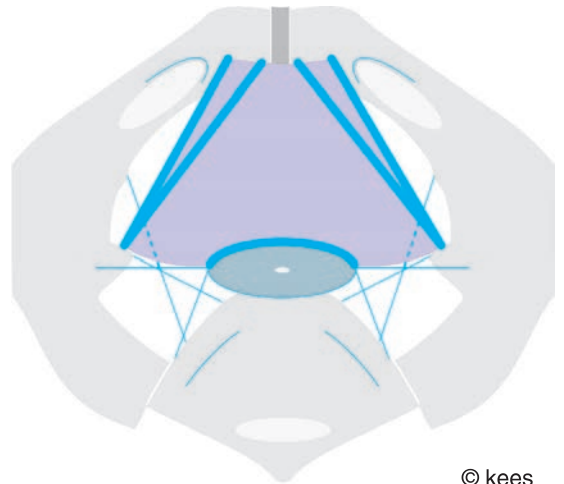
© kees

fig 32 sacrospinous ligaments



© kees

fig 33 pubocervical fascia



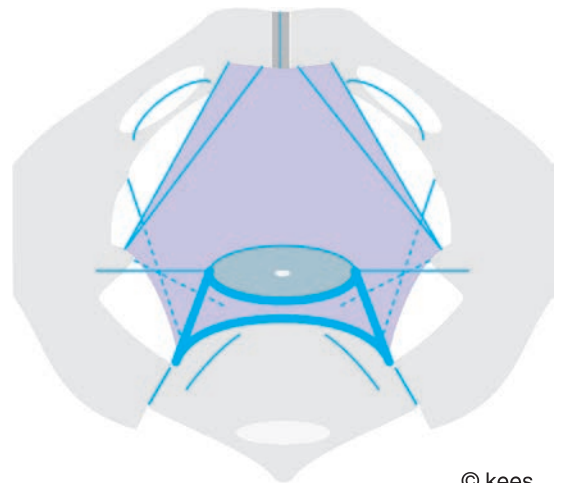
© kees

fig 34 pubocervical fascia



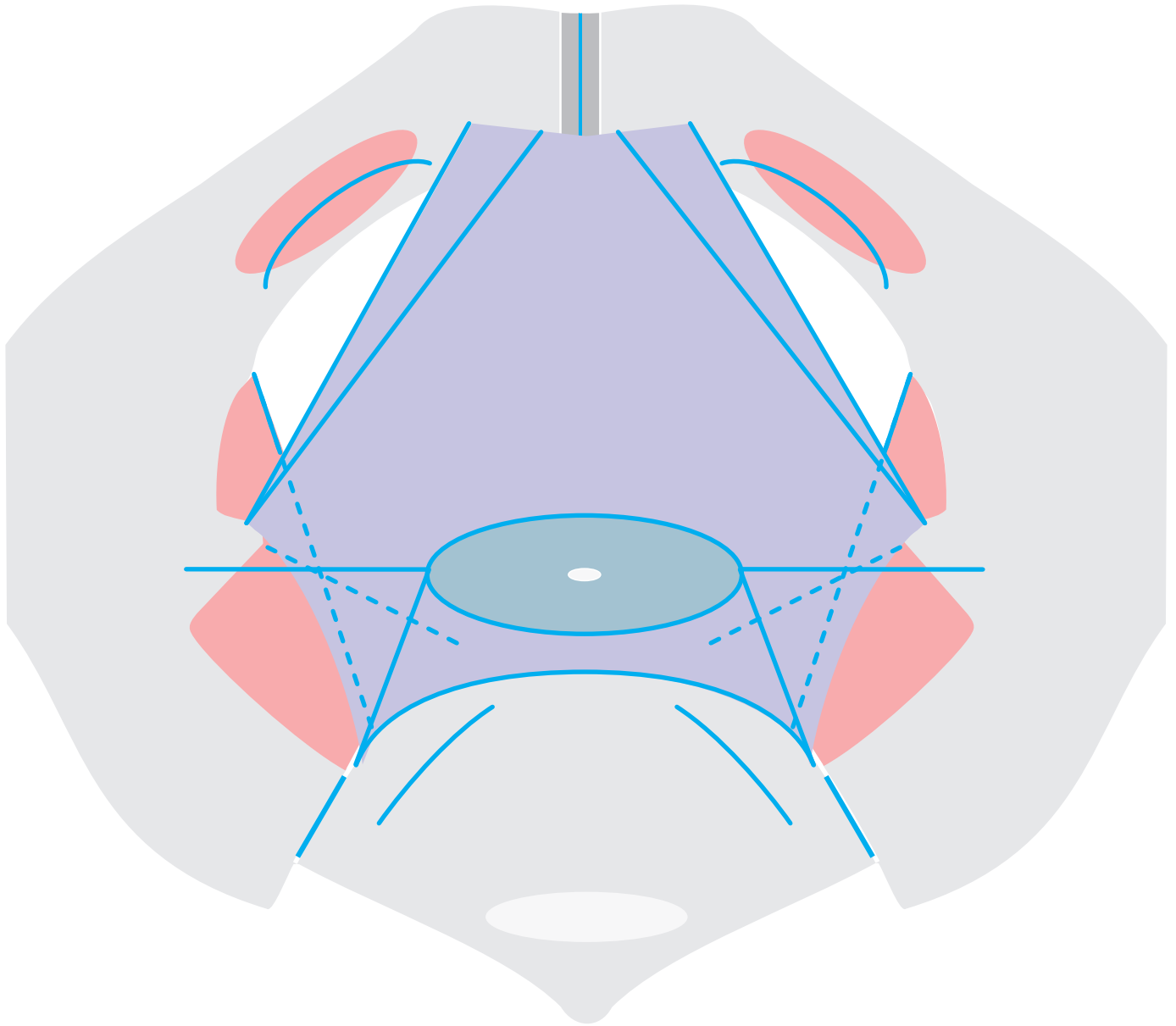
© kees

fig 35 rectovaginal fascia



© kees

fig 36 rectovaginal fascia



© kees

pelvis anatomy

# functional anatomy of female pelvis

## surgical interpretation

### introduction

the functional anatomy of the pelvis structures is a highly complicated interaction of the different pelvis organs as the distal outlet end parts of the urinary tract, the genital tract and the digestive tract; normally in a continent way

the different organs with their arterial blood supply, venous drainage, lymphatic drainage and innervation are embedded into and protected by and encapsulated and/or ensheathed by a complex connective tissue body as corpus intrapelvinum as part of the tela urogenitalis

the most difficult part to understand is the function of the corpus intrapelvinum which consists of a cohesive mixture of collagen, elastin and smooth muscle tissue in a loose, dense or condensed form depending upon the function needed under physiologic and pathologic stress

collagen for strength, elastin for passive elasticity and plasticity and smooth muscle for active tonus and relaxation all under autonomic innervation; see next chapter

however, how hard the author studied he failed to comprehend the various theories since there was a discrepancy between what he found during his extensive obstetric trauma reconstructive surgery and all these theories

the human anatomy does not change, except for under evolutionary impulses; but it seems **another concept** is needed for a comprehensive understanding

though it is based on existing anatomic textbooks, the following constitutes a personal interpretation by the author as a reconstructive surgeon

### function

this whole complex must take care of and is responsible for a more or less independent (and if needed combined) simultaneous functioning of the different organs and tracts from each other like

rapid filling/storage of urine with rapid increase in bladder size and

urine continence until

voluntary micturition with instantaneous decrease in bladder size

rapid filling/storage of liquid\_solid stools/gas with rapid increase in rectum size and stool/flatus continence until

voluntary defecation with instantaneous decrease in rectum size

sexual intercourse with rapid increase/decrease in vagina size and shearing

excretion of menstruation fluid

coping with hormonal changes and ageing changes during the various periods of life

slow increase in uterus size during pregnancy till enormous proportion and pregnancy continence and

coping with hormonal flooding during pregnancy as slow preparation for childbirth with enormous widening/opening of cervix, vagina and outlet diaphragm

remodeling after childbirth during the involution phase of the puerperium

withstand intraabdominopelvic hydrostatic (especially pregnancy) pressure and intraabdominopelvic compression pressure

stabilizing/securing the different organs in their variable anatomic position

under all possible body positions and

under all normal filling stages

prevention of urogenital prolapse

prevention of prolapse of intraperitoneal contents and distal digestive tract

## functional pelvis anatomy

the abdominopelvic cavity, part of which is the pelvis cavity, can be considered as a confined space with contents and hydrostatic and compression pressure

enclosed by the abdominopelvic fascia interna over cephalad the abdominothoracic diaphragm and caudad the pelvis floor ("pelvis diaphragm" and the perineum outlet diaphragm and coccyx), anteriorly the rectus abdominis muscles and pubis bones, bilaterally the abdominus transversus, abdominis obliquus internus et externus and quadratus transversus and iliopsoas muscles and ilium bones, and obturator membrane with obturator internus muscles, levator ani muscles and piriformis muscles and posteriorly by the trunk muscles and lumbar vertebral spine, sacrum and coccyx

the abdominopelvic cavity is divided into an intraperitoneal cavity and an extraperitoneal cavity which again can be subdivided into a retro-, pre- and sub-peritoneal cavity which again can be subdivided into a subdiaphragmatic and a subfascial cavity

so the abdominopelvic cavity in the female can be divided into **five** functional spaces:

the **intraperitoneal space** for the digestive tract enclosed by the parietal peritoneum which is connected to the internal abdominopelvic fascia via the tela subserosa

the extraperitoneal space of the tela subserosa can be subdivided into

the **retroperitoneal space**

and for the pelvis cavity into **three** functional spaces

the **pre/subperitoneal space**

the **subperitoneal subdiaphragmatic space**

the **subperitoneal subrectovaginal fascia space**

### intraperitoneal cavity

for organs of the digestive tract

and enclosed by the parietal peritoneum

though uterus, fallopian tubes and ovaries are situated intraperitoneally and covered by visceral peritoneum they are considered to be pelvis organs

### retroperitoneal cavity

for large blood vessels like aorta and vena cava, lymphatic ducts, sympathetic and para sympathetic nervous system, pancreas, kidneys, ureters etc

and enclosed by

cephalad the thoracoabdominal diaphragm

anteriorly the parietal peritoneum

posteriorly the trunk muscles and lumbar vertebral spine

laterally the lateral abdominal muscles, iliopsoas muscles and ilium bones

caudad the sacrum promontory

### pre/subperitoneal cavity

for the (pelvic part of) ureters, bladder and urethra as distal end parts of the urinary tract and enclosed by

cephalad the parietal peritoneum

anteriorly by the lower abdominal wall and symphysis and most anterior part of the perineum outlet diaphragm

(bi)laterally the pubis bone, obturator membrane and obturator internus fascia

posteriorly by the cervix

caudad by the most anterior part of the perineum outlet diaphragm

## subperitoneal subdiaphragmatic cavity

for the cervix and vagina as distal end parts of the genital tract and enclosed by

cephalad the intrapelvic urogenital diaphragm and parietal peritoneum

anteriorly the most anterior middle part of the perineum outlet diaphragm

posteriorly the parietal peritoneum and sacrouterine ligaments

bilaterally the levator ani muscles as “pelvis diaphragm”

caudad the middle part of perineum outlet diaphragm and rectovaginal fascia

## subperitoneal subrectovaginal fascia cavity

for the rectum, anorectum, anus and external sphincter ani muscle as distal end parts of the digestive tract

and enclosed by

cephalad the rectovaginal fascia

anteriorly the perineal body and rectovaginal fascia

posteriorly the sacrum

(bi)laterally and posteriorly the levator ani muscles

caudad the posterior part of the perineum outlet diaphragm

## pelvis diaphragms and floor

role of anterior vagina wall

### **intrapelvic urogenital diaphragm**

this constitutes a real diaphragm between the intraperitoneal, retroperitoneal and pre/subperitoneal cavities and the subperitoneal subdiaphragmatic and subrectovaginal fascia cavities

between the distal urinary tract and intraperitoneal contents and the distal genital and distal digestive tract

see special chapter

### **levator ani muscles as “pelvis diaphragm”**

on its own this cannot be considered as a real diaphragm since there is a large anterior median opening of 7-8 x 3.5-4 cm; this means that out of the total of 75-80 sq cm of the outlet some 25-30 sq cm are missing or roughly one third

and the two pubococcygeus ledges are more slope-like than horizontal; only the levator plate and coccyx are horizontal in the upright position

the term levator hiatus is misleading since there is no hiatus in the levator ani muscles itself; it is just the open gap between the two pubococcygeus muscle ledges right from its development; so not a pierced thru punched out opening

only the posterior part, the levator plate, can partially counteract the intrabdominopelvic hydrostatic pressure



they cannot prevent urogenital prolapse or enterocele or rectocele; the organs just slide unopposed thru the large anterior median opening once their suspension/support by the corpus intrapelvinum becomes defective

however, they are important since the vagina and rectum are indirectly connected to its fascia; as suspension/connection to the pelvis wall

they play a direct role in the stool continence mechanism to which they are anatomically connected and

only an indirect role in the urine continence mechanism to which they are not connected anatomically; since

actually the ureters, bladder and urethra and their support by the intrapelvic urogenital diaphragm are situated cephalad to the levator ani muscles

they support the perineum outlet diaphragm since there is a firm connection between the two in the region of the perineal body, anus with external sphincter ani muscle and anococcygeal ligament

### **perineum outlet diaphragm**

this constitutes a real diaphragm between the abdominopelvic cavity and the outside as final barrier

together with the end organs it forms part of the anatomic continence mechanisms of the urinary tract, the genital tract and the digestive tract

since the final outlet organs are firmly anchored into it, first these can only prolapse to the outside by a kind of intussusception and

second, contraction of the muscles and increase in its tonus during pelvis floor muscle exercises will contribute directly and positively to the continence mechanisms

it is comparable to the abdominal wall since in quadrupeds it has also the function of a side wall whilst the ventral anterior abdominal wall is the floor; by becoming duopeds this was rotated 90° backwards; and also the superficial perineum space is continuous with the suprapubic subcutaneous space

### **pelvis floor as one functional unit**

the “pelvis diaphragm” is firmly connected to the perineum outlet diaphragm via the perineal body, anorectum and external sphincter ani muscle forming the pelvis floor

whereby the perineum outlet diaphragm is supporting/reinforcing the “pelvis diaphragm” and the other way round

combined they are one functional unit in withstanding intraabdominopelvic hydrostatic and compression pressure; whilst they are also contributing to compression pressure by contraction with increase in their tonus

pelvis floor muscle exercises have a positive effect upon all the continence mechanisms

no role of **anterior vagina wall** as “hammock”

though the vagina is connected/suspended to the pelvis wall by the paracolpium and the anterior vagina wall loosely connected/adherent to the pubocervical fascia

the anterior vagina wall cannot contribute to withstand intraabdominal pressure or to secure other pelvis organs in their variable anatomic position since

the whole vagina (wall + its visceral fascia) is extremely distensible and as such lacks the stiffness characteristics required; as such it also cannot support the anatomic urine continence mechanism

it is hanging onto the intrapelvic urogenital diaphragm in the upright position; as such it is “dragging” this diaphragm down and cannot support this diaphragm to support the anatomic urine continence mechanism

normally there is no intravaginal filling content and as such the vagina is a low- or zero-pressure organ

therefore the vagina cannot prolapse into other high(er)-pressure organs or cavities whilst the other organs can easily herniate into the vagina once there is a defect within the fascia structures of the corpus intrapelvinum in between the organs and the vagina

only in the region of the urethra the anterior vagina wall is firmly fixed to the urethrovesicovaginal fascia as part of the pubocervical fascia as part of the intrapelvic urogenital diaphragm

however, the support to the posterior urethra is not by the anterior vagina wall like a hammock with 2-point fixation which would allow rather large forward and backward swing movements of the posterior urethra wall but

the support is by the intrapelvic urogenital diaphragm with circumferential fixation like the skin of a drum or trampoline allowing slight upward and downward movements depending upon the tonus and relaxation of the smooth muscle fibers of this diaphragm as coordinated by the autonomic nervous system

## structures encountered from symphysis to coccyx/sacrum

### **symphysis pubis**

the symphysis is 5-6 cm broad with an **axis** as to horizontal of 30-45° from caudad (inferior) to cephalad (superior) in the upright position

it forms the anterior bony pelvis

### **arcuate ligament**

transverse ligament connecting the pubic archs just below the symphysis

## **bladder, bladder neck, uv-junction, proximal-mid-distal urethra**

the **anterior** bladder, bladder neck, uv-junction and urethra are attached to and stick to the symphysis by loose connective tissue and a thin fluid film and

are pressed against the symphysis by intravesical/intraabdominal hydrostatic pressure and rest on the symphysis in the upright position

as such these structures can shift friction free against the symphysis during bladder filling and micturition but cannot rotate backwards away from the symphysis

the **posterior** bladder (base), bladder neck, uv-junction and urethra are firmly attached to the pubocervical fascia as part of the intrapelvic urogenital diaphragm and rest on it in the upright position

as such these structures are mobile depending upon the cephalad/caudad mobility of the pubocervical fascia and can rotate backwards away from the symphysis once their support by the intrapelvic urogenital diaphragm becomes defective

the **distal urethra** with **external opening** are firmly anchored into the perineum outlet diaphragm

## **pubocervical fascia**

from the posterior pubis body to the cervix as connected to the (bi)lateral arcus tendineus fasciae; and forms in combination with cervix and broad/cardinal/sacrouterine ligaments the **intrapelvic urogenital diaphragm**; see special chapter

the intact pubocervical fascia secures and stabilizes the (posterior) bladder base/neck, uv-junction and urethra in their anatomic position and as such

supports the female urine continence mechanism; it also stabilizes the cervix anteriorly and bilaterally

the intact pubocervical fascia prevents the bladder, the urethra and the cervix from herniating into the vagina and from prolapsing thru the vagina to the outside

the **axis** of the pubocervical fascia as to horizontal/ground is 25-30° from symphysis to cervix in the upright position

## **pubourethral ligaments**

the anterior and intermediate ligaments are part of the perineum outlet diaphragm whilst the posterior ligaments are part of the intrapelvic urogenital diaphragm

they secure/stabilize the urethra in its anatomic position and as such contribute to the urine continence mechanism

### **anterior vagina wall**

the anterior vagina wall is adherent to the pubocervical fascia and as such indirectly fixed onto the pelvis wall

### **vagina lumen + cervix (also centrum tendineum intrapelvinum) + vagina vault**

the cervix enters the vaginal thru the proximal apical anterior vagina wall (vault); the cervix and posterior vault/fornix separate the intraperitoneal space from the pelvis space; the posterior bladder wall is adherent to the anterior cervix and rests on it in the upright position

the cervix is anchored into the intrapelvic urogenital diaphragm and can be considered its center since all the fascia structures are fixed onto it like pubocervical fascia, cardinal ligaments, rectovaginal fascia and sacrouterine ligaments

so besides being the genital tract anatomic continence mechanism the cervix is also the centrum tendineum intrapelvinum

the vagina itself is a zero-pressure organ since normally there is no filling content

### **posterior vagina wall**

the posterior vagina wall is adherent to the perineal body and rectovaginal fascia or prerectal fascia and as such also indirectly fixed onto the pelvis wall

### **perineal body (centrum tendineum perinei)**

wedge-like connective tissue structure into which the perineum membrane and bulbo spongiosus and transversus perinei muscles radiate and

which stabilizes the anterior ano-rectum and external sphincter ani muscle in their anatomic position and as such supports the stool continence mechanism

it is the center of the perineum outlet diaphragm

### **rectovaginal fascia = prerectal fascia**

in between the posterior vagina wall and anterior (ano)rectum wall as thin connective tissue sheath connected to perineal body and the levator ani muscles fascia via the bilateral arcus tendineus of the rectovaginal or prerectal fascia

far less developed than the pubocervical fascia

### **anterior rectum wall**

covered by peritoneum anteriorly and adherent to the rectovaginal fascia

### **anterior external sphincter ani complex**

covering distal anorectum over 2-3-4 cm and separated from the internal sphincter by the longitudinal muscle layer of the anorectum

### **anterior anorectum wall**

covered by and adherent to preanorectal fascia

### **rectum and anorectum lumen**

empty or filled with stools and/or gas

### **posterior rectum and anorectum wall**

adherent to sacrum, anococcygeal ligament and levator ani muscles; posterior anorectum covered by external sphincter ani complex

### **posterior external sphincter ani complex**

the external sphincter ani is thicker posteriorly than anteriorly

### **levator ani muscles**

originating anterobilaterally from pubis bone and arcus tendineus of levator ani muscle like a shallow bowl around lateral vagina walls and lateral rectum walls and underneath anorectum/rectum and inserting posteriorly into levator plate, anococcygeal ligament and coccyx bone

### **levator plate**

posterior fusion of levator ani muscles in a horizontal plane in the upright position

### **anococcygeal ligament**

fixes anorectum to coccyx; the levator ani muscles radiate partially into this ligament

### **sacrum and coccyx**

these form the posterior bony pelvis

what is difficult to describe is the anatomic position of connective tissue between the organs and pelvis wall, and between the organs as part of the static and dynamic

## corpus intrapelvinum

see special chapter

which constitutes a connective-tissue “organ” and consists of a cohesive mixture of collagen, elastin and smooth muscle tissue/fibers in a loose, dense or condensed form as needed according to physiologic stress

for lining the pelvis walls as parietal fascia, protecting the organs as visceral fascia, for connection/suspension of the organs to the pelvis wall, for loose or firm connection of organs to each other and for ensheathing blood vessels, lymphatic vessels and nerves for blood supply and innervation of the pelvis organs

collagen for strength, elastin for passive elasticity and plasticity and smooth muscle for dynamic tonus or relaxation as innervated by the autonomic nervous system

its 3-dimensional mesh-like configuration and basic functions are easy to understand but it is difficult to understand and visualize the full anatomic and dynamic extent of this very important body

it fills up the spaces between the organs and the pelvis wall and the spaces between the different individual organs where it may condense as ligaments or fasciae

or stay loose between the different organs so that the organs can fill up and move and empty and move independently from each other and withstand the shearing forces during sexual intercourse or childbirth

it can remodel according to tissue forces and physiologic stress if the need arises by enlarging and strengthening of its fibers (during pregnancy), or by debulking (during involution phase post partum)

like all the pelvis organs it is influenced by hormones, by ageing, by obstetric trauma

## functional anatomic female continence mechanisms

### female urine continence mechanism

the anatomic female urine mechanism comprises the bladder neck with both detrusor loops, the uv-junction and the whole urethra from internal to external opening over a total length of 4-5 cm with continence potential over its whole length under physiologic stress

there is an internal smooth muscle sphincter and an external striated muscle rhabdo sphincter with washer effect by the mucosa and submucous vascular plexus

the distal urethra and external opening are anchored into the pierced thru punched out opening in the perineum outlet diaphragm and so stabilized in their anatomic position

the anterior urethra wall is adherent to the posterior symphysis by loose connective tissue and a thin fluid film which allows the anterior urethra wall to shift against the symphysis friction free, though little; however it cannot rotate backwards away from the symphysis

the posterior urethra wall is firmly adherent to the pubocervical fascia with pubourethral ligaments as part of the intrapelvic urogenital diaphragm stabilizing the bladder neck, uv-junction and urethra in their anatomic position; the posterior urethra wall can rotate backwards away from the symphysis once its anatomic support becomes defective

in the upright position the bladder and urethra rest upon the symphysis anteriorly and upon the intrapelvic urogenital diaphragm posteriorly

at not a single point is there a direct connection/contact of the urethra, uv-junction and bladder neck with the levator ani muscles in both male and female; as such

the levator ani muscles do not play a direct role; however indirectly, they may contribute for a short time since

contraction (with indirect squeezing of bilateral and posterior vagina walls) will lead to anterior/cephalad movement of the nonsqueezed anterior vagina wall and attached pubocervical fascia towards the symphysis; and also by the increased compression pressure within the vagina according to pascal's law; whilst

the striated urethra rhabdosphincter fibers contract as well and the tonus of the smooth muscle fibers within the intrapelvic urogenital diaphragm increases by reflex action

increase in tonus of the **intact** pubocervical fascia as anterior part of the intrapelvic urogenital diaphragm leads to an anterior/cephalad movement of the pubocervical fascia with stabilization of the adherent posterior urethra, uv-junction and bladder neck

and as such will contribute to the intrinsic closing forces since the posterior urethra wall "rotates forwards" towards the anterior urethra wall

though it is the total effect of all factors combined the internal smooth muscle sphincter seems to be the major force

### **female genital uterus continence mechanism**

the anatomic genital continence mechanism is situated within the whole cervix from the isthmus to the cervix opening as internal smooth muscle sphincter

the cervix itself is anchored into the pierced thru punched out opening in the intrapelvic urogenital diaphragm and as such is supported by this diaphragm; and also supporting this diaphragm via the cardinal ligaments

whilst the vagina builds a conduit towards the outside and also a tough structure for sexual intercourse

the distal vagina with opening are anchored into the pierced thru punched out opening in the perineum as outlet diaphragm with the bulbospongiosus muscles as external striated sphincter

the internal smooth muscle sphincter seems to be the major force whilst actually the external sphincter does not play a role of importance in genital continence

## female stool continence mechanism

the anatomic female stool continence mechanism comprises the anorectum (internal sphincter) and external sphincter ani complex also over a total length of 4-5 cm

in colorectal surgery a rectum resection with continent end-to-end sigmoidoanorectomy is only advisable if the remaining distal healthy anorectum stump is at least 4 cm long, the longer the anorectum stump the better the chance of stool continence

the anorectum is stabilized/secured in its anatomic position by the anococcygeal ligament and levator plate posteriorly and by the intact perineal body with bulbospongiosus and transversus perinei muscles anteriorly and (bi)laterally

the distal anorectum with external sphincter ani are anchored into the pierced thru punched out opening in the perineum outlet diaphragm

the levator ani muscles do play a direct role, especially the puborectalis part since on contraction they squeeze the anorectum and move it anteriorly and cephalad

though it is the total effect of all factors combined the internal smooth muscle sphincter seems to be the major force

## discussion

there is an enormous amount of research done mostly based on postmortem dissection and indirect imaging; however, the author failed to understand the functional anatomy and the resulting theories could not be confirmed by him in the living patient

the author gives a very personal interpretation of the functional anatomy as based on findings and evidence-based results during and following his extensive obstetric trauma reconstructive surgery

this does not mean he is right since it is the view of a surgeon and not of an anatomist; but definitely **another concept** is needed

the notion that the levator ani muscles are of utmost importance for the female urine continence mechanism and for (the prevention of) prolapse cannot be confirmed by the author; please look at the functional anatomic configuration

there is nowhere direct contact between the **midline** urethra/uv-junction/bladder neck (anatomic continence mechanism) and the **lateral** levator ani muscles and

together with their support by the intrapelvic urogenital diaphragm they are situated cephalad to the levator ani muscles; so out of direct influence

the urethra lies anteriorly at the midline against the symphysis and the nearest point the levator ani muscles come to the urethra is bilaterally 1.5 cm away at the most anterior part of the arcus tendineus of levator ani muscles (atlam); then the atlam runs immediately laterally and posteriorly to the ischial spine farther away from the midline and urethra



even the only possible minimal indirect connection via a narrow triangular fascia sheath between the arcus tendineus fasciae and the arcus tendineus of levator ani muscle and obturator fascia is cephalad to (the action of) the levator ani muscles

so contraction cannot have a direct effect upon the urethra, uv-junction and/or bladder neck

the only indirect thing possible on contraction is that by compression of the lateral/posterior vagina walls the anterior vagina wall with attached pubocervical fascia moves cephalad/anteriorly with forward rotation of the posterior urethra wall towards the symphysis and as such provides a better support

as well the author never did anything to the levator ani muscles during his extensive obstetric trauma surgery but still achieved full continence once the different defects in the intrapelvic urogenital diaphragm, like median, transverse, curved, quartercircular or semicircular, were repaired according to the principles of reconstructive surgery

the notion that the intact levator ani muscles prevent prolapse cannot be confirmed; see chapter on prolapse

to the author it looks far-fetched since there is nowhere a direct connection between the prolapse-prone organs and the levator ani muscles as “pelvis diaphragm” with large hernia-prone opening

consider the tube-like configuration of the pelvis space and all the different intrapelvic structures between the pelvis floor and the pre/subperitoneal and intraperitoneal spaces; by what mechanism would the action of the levator ani muscles contribute

the diameter recta between the underside of symphysis and tip of coccyx is 9-9.5 cm and the levator ani muscles are fixed to coccyx/anococcygeal ligament; and the distance from ischial spine to coccyx is minimally 5-6 cm

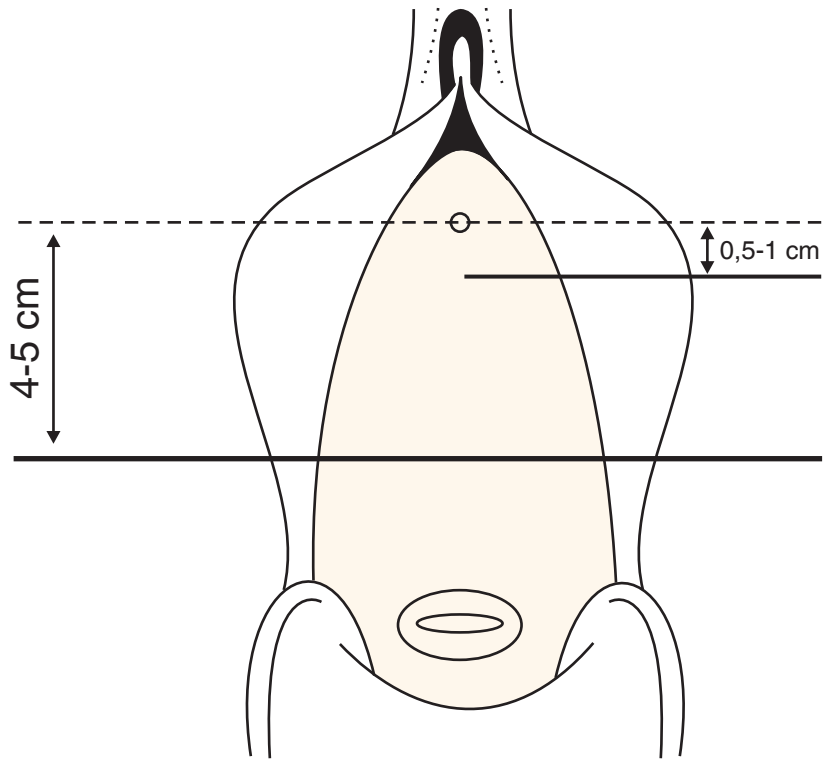
so at no point it is possible that the (posterior union of the) levator ani muscles can come into direct contact with the intrapelvic urogenital diaphragm by contraction or anything physiologic

prolapse is not thru the levator ani muscles and other pelvis floor structures but the prolapse is thru defects in the intrapelvic urogenital diaphragm due to which and the bladder and/or cervix are no longer supported and start to herniate into the vagina

if there is prolapse, cystocele or 2° or 3° cervix prolapse, these slide “over” the levator ani muscles and other pelvis floor structures thru the vagina towards the outside

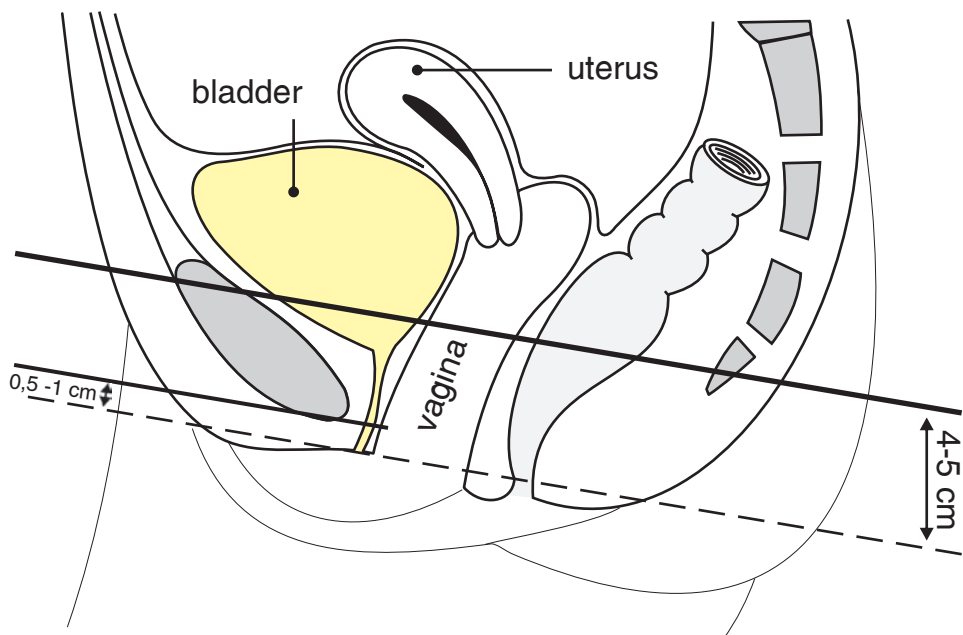
this process cannot be prevented or stopped by the levator ani muscles or other pelvis floor structures, either relaxed or contracted

as well the author never did anything to the levator ani muscles during his extensive prolapse surgery as part of the obstetric trauma but still achieved good results



© kees

fig 37 urine continence/closing mechanism: frontal



© kees

fig 38 urine continence/closing mechanism: sagittal

# corpus intrapelvinum

multifunctional connective tissue body of pelvis

as archaic matrix

## introduction

the whole complex of intrapelvic connective tissue is called the corpus intrapelvinum or connective tissue body of pelvis; as matrix for the organs with their arterial blood supply, venous drainage, lymphatic drainage and innervation

it is also called endopelvic fascia or fascia endopelvina (conjugans), however, its main component consists of smooth muscle tissue/fibers

though its basic anatomic structure and functions are easy to understand it is difficult to comprehend and visualize its exact anatomic extent with highly specialized functions according to the different physiologic needs

especially since there are no clear demarcations which make it difficult to demonstrate this body with different structures by dissection and/or indirect imaging

however, it is only by studying its full anatomic extent and understanding its functions that progress will be made in reconstructive pelvis surgery

since weakness and defects in this important corpus intrapelvinum are responsible for the development of genuine intrinsic incontinence, urogenital prolapse, enterocele and rectocele

the amount of literature is enormous with confusing and contradicting terminology and various complicated theories

however, the anatomy and functional anatomy do not change and the author would like to give an outline as based on existing anatomic textbooks, especially

**lehrbuch der topographischen anatomie** as written by **anton hafferl** as second edition from 1957

by analyzing the topographic position in relation to the urinary and genital tract the paramount role of the levator ani muscles in these theories seems to be overvalued and highly questionable

the author thinks **another concept** is needed with regard to the functional anatomic urine (in)continence mechanism and urogenital anatomic position and prolapse

therefore he would like to introduce the concept of **intrapelvic urogenital diaphragm** as part of the corpus intrapelvinum as first line for counteracting the intraabdominal hydrostatic and compression pressure, as support of the urine continence mechanism and for securing the organs in their variable anatomic position; see next chapter

## basics of serous membranes

the body cavities are enclosed by bones and muscles covering the bone and muscles bridging the gaps in between the bones

the **fascia interna** is the total fascia inner lining of the cavity

the **serosa** (peritoneum, pleura) is connected to this fascia by

the **tela subserosa**

depending upon the width in between the fascia and the serosa the tela subserosa may develop from minimal with its basic loose archaic texture to extensive with a cohesive mixture of collagen, elastin and smooth muscle tissue as connective tissue body in a loose, dense or condensed form

the intracavity organs are embedded into the tela subserosa together with their blood supply, venous drainage, lymphatic drainage and innervation; whilst the tela subserosa also connects/suspends the organs to the cavity wall and each other

## abdominopelvic cavity

the total fascia inner lining of the abdominopelvic cavity is called fascia abdominis interna; the serosa is called parietal peritoneum; the connective-tissue layer connecting the fascia abdominis interna to the parietal peritoneum is called the tela subserosa

the width between the internal fascia and peritoneum is small at the upper anterior abdominal wall up to the umbilicus and at the thoracoabdominal diaphragm and the fascia interna may “fuse” with the parietal peritoneum

however, the distance between the parietal peritoneum and posterior abdominal wall, anterior caudal abdominal wall and pelvis wall becomes wider and wider resulting into extensive development of the tela subserosa as tela urogenitalis

## pelvis cavity

the total fascia inner lining of the pelvis cavity is part of the fascia abdominis interna; and here it is called

the fascia pelvis parietalis

the serosa is called peritoneum parietale

the tela urogenitalis is that part of the tela subserosa which is filling up the large gap between the fascia pelvis parietalis and peritoneum parietale

the intrapelvic organs are embedded into the tela urogenitalis together with their arterial blood supply, venous drainage, lymphatic drainage and innervation; whilst the tela urogenitalis also connects/suspends the organs to the pelvis wall and each other

from the tela subserosa urogenitalis 3 structures develop

### fascia visceralis

encapsulating the organs and ensheathing the blood/lymphatic vessels and nerves

### corpus intrapelvinum

cohesive mixture of collagen, elastin and smooth muscle tissue/fibers in a loose, dense or condensed form; its main component is **dynamic** smooth muscle tissue/fibers

### loose connective tissue

filling up the spaces not occupied by the corpus intrapelvinum

## fascia visceralis

as part of the tela urogenitalis which encapsulates the organs and then is named after the organ like fascia visceralis vesicae = visceral bladder fascia; and which as well ensheaths the blood and lymphatic vessels and the nerves

the space in between the fascia visceralis and the organ wall is filled up by loose connective tissue allowing the organs like the bladder to expand and deflate rapidly by filling and emptying within a short time span

when the organ does not expand and deflate rapidly like the uterus which grows slowly during pregnancy the fascia visceralis “fuses” with the organ wall and grows slowly together with the uterus; after emptying by childbirth it involutes slowly together with the uterus during the puerperium

## corpus intrapelvinum = connective tissue body of pelvis

as part of the tela urogenitalis; it constitutes a multifunctional connective tissue organ/body and consists of a cohesive mixture of collagen, elastin and smooth muscle tissue fibers in loose, dense or condensed form according to whatever is needed

collagen for strength, elastin for passive elasticity and plasticity and smooth muscle fibers for active dynamic tonus and relaxation under autonomic nervous system coordination

the smooth muscle component is the main component; even if some parts of it are called fascia or ligament it is still prevalent

its extensive 3-dimensional mesh-like structure ensures a seamless combination of static and dynamic functions

as a whole together with components of the organ walls as embedded into it, the corpus intrapelvinum is the major force in resisting hydrostatic and compression intraabdominal pressure due to its non-fatigue tonus which can be increased by reflex action and as such contributes to compression pressure

the pelvis floor with its large hernia-prone openings is secondary in taking care of the rest pressure

it also protects the organs with their supply from physiologic trauma during walking, sexual intercourse and childbirth

the specialized parts of it are called fasciae, septa, ligaments, plicae which all together form the corpus intrapelvinum each with a specialized function for the organs with their supply and then combined for the whole biomechanicophysiology of the pelvis cavity

it has to be considered as one multifunctional body where the basic archaic texture has developed into individual specialized structures according to the physiologic needs

the space between one organ and another or between an organ and the adjacent cavity wall is called a spatium filled up by connective tissue in a condensed form as septum/fascia or in a loose form or in a loose form with a thin fluid film

it embeds the organs and their arterial blood supply, venous drainage, lymphatic drainage and innervation; and stabilizes and secures the organs in their variable anatomic position depending upon the degree of filling of the organ itself or filling of the adjacent organ(s); in whatever body position

it suspends/connects the intrapelvic organs to the pelvis wall with so called pillars for arterial blood supply, venous drainage, lymphatic drainage and innervation

it is responsible for the blood flow inside the valve less intrapelvic veins towards the vena cava inferior

it allows the organs to expand rapidly by filling and deflate rapidly by emptying

it allows the organs to move smoothly and independently from or simultaneously with each other

depending upon the physiologic needs it condenses to dense fascia plates or septa in between the organs and ligaments from the organs to the (bi)lateral pelvis wall and also loose structures like plicae; since the ligaments are smooth muscle tissue they are called muscles as well

though it is one continuous 3-dimensional mesh-like body it is subdivided into overlapping para- structures

paracystium

that part of corpus intrapelvinum into which the bladder is embedded with condensation as bladder pillar at posterior bladder base cephalad to the ischial spine containing the blood and lymphatic vessels and nerves, and the pelvic ureter; connecting/suspending the bladder to the pelvis wall

parametrium

that part of corpus intrapelvinum which embeds the uterus/cervix, tubes and ovaries with condensation as uterovaginal pillar at uterus isthmus in the frontal plane thru and cephalad to the ischial spine containing the blood and lymphatic vessels and nerves and the pelvic ureter; connecting/suspending these organs to the pelvis wall

paracolpium

that part of corpus intrapelvinum which embeds the vagina with condensation as uterovaginal pillar in the frontal plane thru and cephalad to the ischial spine containing the blood and lymphatic vessels and nerves; connecting/suspending the vagina to the pelvis wall

paraproctium

that part of corpus intrapelvinum which embeds the rectum with condensation as rectum pillar in the region of the ischial spine containing the blood and lymphatic vessels and nerves; connecting/suspending the rectum to the pelvis wall

and into the condensed parts in between the organs like septum; these are not separate parts but fit into the corpus intrapelvinum as part of the fascia between the organs like pubocervical fascia

septum vesicocervicale

in between posterior bladder and anterior cervix as vesicocervical fascia

septum vesicovaginale

in between posterior bladder and anterior vagina wall as pubocervical fascia

septum rectovaginale

in between anterior rectum and posterior vagina wall and is fixed to centrum tendineum perinei (perineal body) as rectovaginal fascia

the space between the septa and the visceral fascia of the organs is filled up by loose connective tissue allowing friction free movement of the organ wall against the septum; ideally this is the layer or space of interest for surgeons in bloodless dissection

spatium prevesicale

between bladder and symphysis in continuity bilaterally with

spatium paravesicale

between bladder and (bi)lateral pelvis wall

all filled up by loose connective tissue and thin adhesive fluid film allowing the bladder wall to slide against the pelvis wall and anterior abdominal wall without coming loose

spatium vesicocervicale

between bladder and cervix

spatium vesicovaginale

between bladder and vagina

spatium rectovaginale

between vagina and rectum and up to and into perineal body

spatium pararectale

(bi)laterally between rectum and pelvis wall in connection with

spatium retrorectale

between rectum and sacrum

continues cephalad into the spatium retroperitoneale

it reacts to hormones and reconfigures under physiologic stress

one highly specialized structure consisting of pubocervical fascia in combination with cervix, cardinal ligaments, broad ligaments and sacrouterine ligaments in between the

bladder, uterus and peritoneum and the vagina forms within the corpus intrapelvinum as a whole a dynamic functional intrapelvic urogenital diaphragm

the cervix is anchored into the corpus intrapelvinum and as such if present is part of this diaphragm

actually, the cervix can also be considered the centrum tendineum intrapelvinum since it constitutes the center of the intrapelvic urogenital diaphragm and

all the different structures of the corpus intrapelvinum like pubocervical fascia, cardinal ligaments, rectovaginal fascia and sacrouterine ligaments are firmly connected to it

the function of this diaphragm will be explained in the next chapter

## loose connective tissue

as part of the tela urogenitalis in a loose archaic form filling up the spaces not occupied by the corpus intrapelvinum; these spaces are of interest to the surgeon for a bloodless dissection

this allows friction-free movement/sliding of the organ wall against the structures of the corpus intrapelvinum without becoming loose from each other

and together with a thin adhesive fluid film it allows the bladder wall to slide against the anterior abdominal wall and anterior and lateral pelvis wall without becoming loose

and ensuring that the anterior urethra wall is always adherent to the posterior symphysis and as such does not rotate; not even if the posterior urethra wall rotates backwards away from the posterior symphysis due to defective connective tissue support and then resulting into progressive funneling or vesicalization of the urethra starting proximally

## innervation

like all other structures in the human body the corpus intrapelvinum is under control and coordination by the autonomic nervous system; via a complicated reflex mechanism

the sympathetic system for stimulation by increasing the tonus of the smooth muscle fibers and the parasympathetic system for relaxation of the smooth muscle fibers

since its main component is smooth muscle tissue/fibers the corpus intrapelvinum forms a highly dynamic body due to its non-fatigue tonus which can be increased or relaxed immediately upon whatever is needed at a certain moment by reflex action



## discussion

how to describe an important 3-dimensional mesh-like collagen, elastin and smooth muscle connective tissue body without clear demarcations in its full anatomic extent and full **dynamic** multi-functionality

as based on findings during his obstetric trauma surgery and evidence based results it became clear that another concept was needed; as one major function of the corpus intrapelvinum

the problem is that since there are no clear demarcations between this body and the organs except for the visceral organ fascia and between the different structures of the corpus intrapelvinum it is difficult to demonstrate it as a whole and/or demonstrate its different structures by surgical dissection and/or indirect imaging

however, once one starts looking for this dynamic corpus and its different structures as a surgeon one will find it and its structures and then starts realizing its **paramount** importance for the functional pelvis anatomy

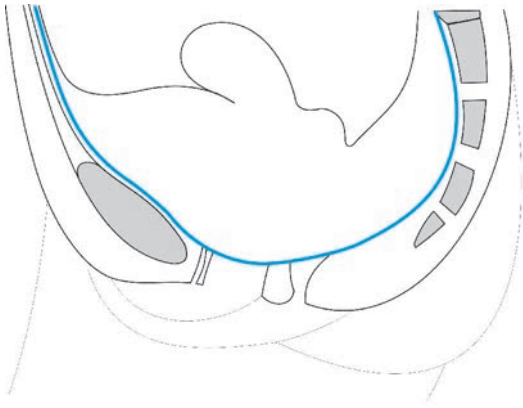
though the different structures have their own specific function their actual strength is that their function will be reinforced by the simultaneous function of the whole corpus intrapelvinum as one dynamic biomechanicophysiological unit

embedding the organs and their arterial blood supply, venous drainage, lymphatic drainage and innervation and being

responsible for the independent physiologic functioning of the organs, for stabilizing/securing the organs in their variable anatomic position, for suspending/connecting the organs to the pelvis wall and to each other, for protecting the organs and their supply against physiologic trauma during walking, sexual intercourse and childbirth and for supporting the continence mechanisms of the urinary, genital and digestive tract

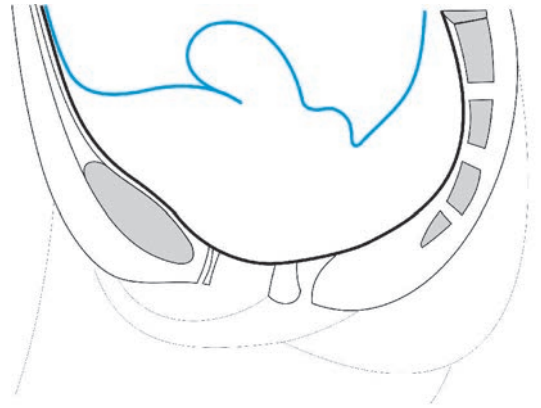
genuine intrinsic urine incontinence, urogenital prolapse like cystocele and uterovaginal prolapse, intraabdominal content prolapse like enterocele and digestive prolapse like rectocele are all due to localized defects in the corpus pelvinum in isolated form or combined

though the author believes strongly in this concept, time and evidence-based results and challenges by other reconstructive surgeons will tell if he is right or wrong



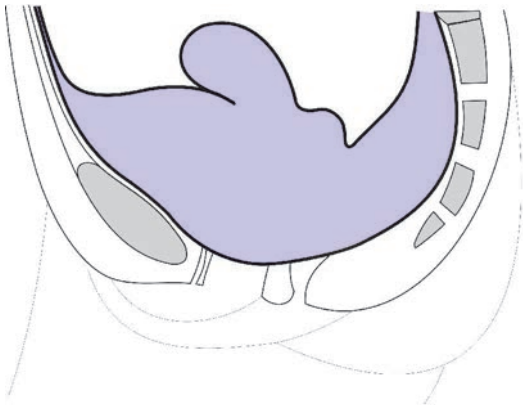
© kees

fig 39 fascia pelvis parietalis



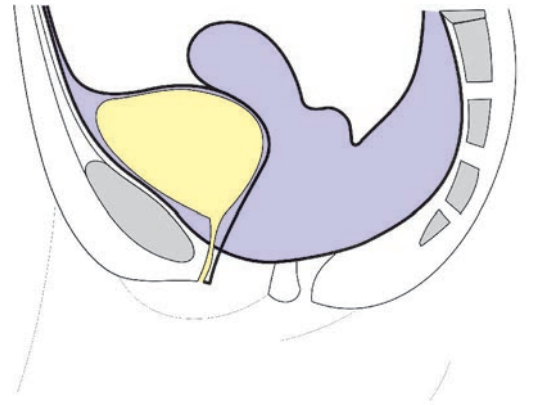
© kees

fig 40 peritoneum parietale



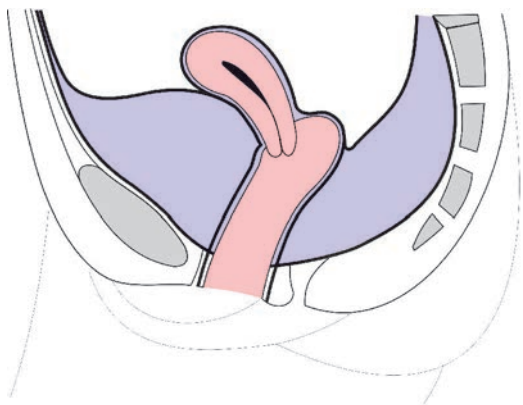
© kees

fig 41 tela urogenitalis



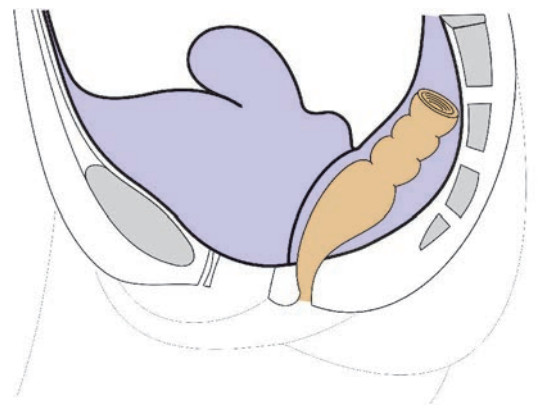
© kees

fig 42 urinary tract space



© kees

fig 43 genital tract space



© kees

fig 44 digestive tract space

# **intrapelvic urogenital diaphragm**

**in the female**

**with cervix as its central point**

## **introduction**

the intrapelvic organ and organ support situation in the female differs radically from the situation in the male by the interposition of the large female genital tract in between the distal urinary tract anteriorly and the distal digestive tract posteriorly

all embedded into the corpus intrapelvinum of the tela urogenitalis, together with their vascular, lymphatic and nervous supply

though the situation of the “pelvis diaphragm” is more or less the same since the levator ani muscles are not affected; except for a wider pelvis

the perineum outlet diaphragm is severely weakened by the large vagina opening; so instead of two now a third and large opening has been pierced thru punched out

so the pelvis floor in the female is prone to dysfunctioning

there is increased hydrostatic intraabdominal pressure due to the weight of the female genital organs; especially during pregnancy

also the support of the anatomic female urine continence mechanism changed since in the male it is well supported by the prostate

as compensation in order to support the female bladder and urethra and the uterus and cervix and to withstand the intraabdominal pressure the corpus intrapelvinum formed a functional dynamic structure as the author would like to call the

## **intrapelvic urogenital diaphragm**

from the pubis bone bodies anteriorly to the sacrum posteriorly and circumferentially connected to the pelvis wall like the skin of drum or trampoline with the cervix as its center; and fusing anteriorly with the perineum outlet diaphragm

in between the distal urinary tract and intraperitoneal contents and the distal genital and distal digestive tracts

with a small opening anteriorly for the urethra and a larger one posteriorly for the rectum

since the cervix is firmly anchored into the central pierced thru punched out opening it becomes the centrum tendineum intrapelvinum as well; since all the fascia structures are firmly anchored onto it

it consists of a mixture of connective tissue for strength, elastin for passive elasticity and plasticity and smooth muscle fibers for active dynamic non-fatigue tonus and relaxation under autonomic nervous innervation

it is the first line of counteracting the hydrostatic intraabdominal pressure and contributes to compression pressure by increase or decrease of its tonus; especially since its main component is smooth muscle fibers

whilst the rest pressure is dealt with by the pelvis floor structures, especially by the perineum outlet diaphragm

it supports the posterior urethra, uv-junction and bladder neck in their anatomic position and as such contributes to the anatomic urine continence mechanism

it prevents the posterior urethra, posterior bladder (base), cervix and intraperitoneal contents from herniating into the vagina

it is divided into specialized parts as the pubovesical/posterior pubourethral ligaments, pubocervical fascia, arcus tendineus fasciae, cardinal/broad ligaments, rectovaginal fascia and sacrouterine ligaments with the cervix as centrum tendineum intrapelvinum since all its fascia/ligament structures are firmly connected to it

#### **pubovesical/posterior pubourethral ligaments (= muscles)**

anchoring the most anterior part of the pubocervical fascia as part of the intrapelvic urogenital diaphragm onto the pubis bone bodies and

securing the posterior proximal urethra, uv-junction and bladder neck in their anatomic position and so supporting the female urine continence mechanism

once they become defective intrinsic stress incontinence may develop

#### **pubocervical fascia**

like a triangle from the pubis bone body and bilateral aff to the cervix as the anterior part of the intrapelvic urogenital diaphragm as part of the corpus intrapelvinum

the fascia is well developed and seems to consist of longitudinal smooth muscle fibers (from anterior towards posterior) and underneath the mid/distal urethra transverse smooth muscle fibers (in between the 2 median inferior surfaces of the pubis bones) interwoven by collagen and elastin

the longitudinal arrangement seems likely since longitudinal median defects are found intraoperatively at genuine incontinence, cystocele and cervix prolapse surgery

the anterior transverse arrangement seems likely since the median longitudinal defects stop at 1.5-2 cm to the external urethra opening

the intact pubocervical fascia secures and stabilizes the (posterior) bladder base/neck, uv-junction and urethra in their anatomic position and as such supports the female urine continence mechanism; it also stabilizes the cervix anteriorly and bilaterally

the intact pubocervical fascia prevents the pre/subperitoneal contents bladder base /uv-junction/urethra and the cervix from herniating into the vagina

the **axis** of the pubocervical fascia as to horizontal/ground is 25-30° from symphysis to ischial spine in the upright position

the posterior wall of the urethra, uv-junction and the bladder trigonum are not expanding during the asymmetric filling of the bladder; therefore these structures are firmly fixed to the pubocervical fascia whilst

the anterior vagina wall is rapidly expanding and deflating with shearing during sexual intercourse and even more during childbirth and as such is loosely connected/fixed to the pubocervical fascia, except for in the region of the urethra where it is firmly fixed to it

### **arcus tendineus fasciae = atf**

as bilateral fixation/insertion of the intrapelvic urogenital diaphragm/pubocervical fascia whilst

the arcus tendineus fasciae is further connected to the lateral pelvis wall (arcus tendineus of levator ani muscle and oburator internus muscle fascia) via a narrow triangular fascia sheath

### **cervix**

the cervix is considered to be the centrum tendineum intrapelvinum since all the fascia structures of the intrapelvic urogenital diaphragm are firmly anchored onto it whilst the cervix itself is firmly anchored into the central pierced thru punched out opening within the intrapelvic urogenital diaphragm

### **cardinal ligaments and broad ligaments**

since they radiate into the cervix they support the intrapelvic urogenital diaphragm restricting its downward movement

### **sacrouterine ligaments**

as posterior fixation of the intrapelvic urogenital diaphragm onto the sacrum since they fix/connect the cervix posteriorly onto the rectum and sacrum

with lateral fixation to the pelvis wall (ischiococcygeus muscles, sacrospinous ligaments and priformis muscle) via fascia sheaths

### **(part of the) rectovaginal fascia**

In between the vagina and rectum and anchored onto the posterior cervix in between the sacrouterine ligaments

### **weakest point in the intrapelvic urogenital diaphragm (pubocervical fascia)**

considering the anterior cone-like triangular shape with the narrowest at the pubis bones and the broadest in between the ischial spines the weakest point is in the median at the anterior cervix

and the broader the pelvis (with broad span) the more prone for median defects and as such for stress incontinence, urethrocele, cystocele and cervix prolapse

## mechanism of pathophysiologic action

the downward intraabdominal pressure upon the intrapelvic urogenital diaphragm may lead to defects within this diaphragm

the downward pressure increases during the course of pregnancy with highest pressure at the median where the cervix is anchored into the intrapelvic urogenital diaphragm

the broadest part of the fascia is in between the ischial spines where it stabilizes and secures the cervix and

this is exactly where splitting/division of the longitudinal smooth muscle/collagen fibers at the median starts and then continues from proximally to distally

normally the most distal 1-2 cm stay intact since the short span is able to withstand the pressure and the smooth muscle/collagen fibers are transverse instead of longitudinal

it is good to remember that during childbirth itself the pressure changes from downward caudad to upward cephalad and that semicircular compression and shearing occur at where the fascia is attached to pubis and atf

so, other locations are possible as well

in prolonged obstructed labor pressure necrosis may develop and lead to anatomic tissue loss defects at any location within the intrapelvic urogenital diaphragm

then there may be direct trauma (penetration, surgery) and trauma due to infection

## defects within the intrapelvic urogenital diaphragm

there are two types of defects viz defects without anatomic tissue loss like those due to intraabdominal pressure or shearing and defects with anatomic tissue loss varying from minimal to (sub)total loss like those due to pressure necrosis in prolonged obstructed labor or due to infection or due to surgery

### defects without anatomic tissue loss

since it is the first line of withstanding intraabdominal hydrostatic pressure especially during pregnancy and also withstanding shearing forces during sexual intercourse and physiologic vaginal childbirth

it is clear that defects may develop weakening the intrapelvic urogenital diaphragm in varying degrees from minor to extensive

it is good to realize that during pregnancy the direction of long-term pressure is from cephalad to caudad whilst during childbirth the short-term pressure is from caudad to cephalad upon this diaphragm

since it has multiple functions, like supporting the urine continence mechanism and securing the organs in their anatomic position, defects within the diaphragm will have different effects depending upon their location

the possibilities are as following: anterior, median, lateral, central and posterior; isolated or in any combination

### **anterior defects**

with weakening of the urine continence support since the posterior urethra wall will “rotate backward” away from the symphysis causing vesicalization of the (proximal) urethra since fixed/adhesive anterior urethra wall  
by this mechanism genuine or postrepair intrinsic stress incontinence develops

### **median longitudinal defects**

depending upon its location the posterior urethra, bladder base may herniate thru this defect into the zero-pressure vagina and eventually prolapse to the outside  
only if there is also concomitant weakening of the support or dorsal-directed pull on the posterior urethra wall towards the sacrum the urine continence mechanism may be involved

### **central defect**

the cervix/uterus will herniate thru this defect into the vagina and then may prolapse unopposed to the outside thru the hernia-prone opening in the pelvis floor dragging the anterior vagina wall with it like intussusception  
only infrequently if there is concomitant weakening of the support or dorsal-directed pull on the posterior urethra wall towards the sacrum the urine continence mechanism may be involved  
normally there is full urine continence in total 3° uterus/cervix prolapse even with a urethra length of only 0.5-1 cm  
however, with increased longitudinal bladder diameter, shortened urethra and narrow external urethra opening

### **posterior defect**

this will result in herniation of the intraperitoneal contents into the zero-pressure vagina

### **lateral defects at atf**

this will result in loss of tonus of the intrapelvic urogenital diaphragm and an increase in the caudad/cephalad movements but not in herniation/prolapse of an organ thru this defect

### **lateral defects of the fascia sheath in between the atf and atlam**

this will result in medial displacement of the atf with loss of tonus and hypermobility of the intrapelvic urogenital diaphragm but not in herniation/prolapse of an organ thru this defect

### **other location**

due to penetrating trauma or forceps delivery or vacuum delivery

### **defects with anatomic tissue loss**

it is good to realize that in any obstetric urine fistula there is anatomic tissue loss of the pubocervical fascia as well

therefore in obstetric trauma surgery one should make an effort to identify the fascia defects and repair them together with the fistula

the extent and location of pressure necrosis lesions in prolonged obstructed labor may be from minimal to extensive and from one location to the other in an endless variation which makes the obstetric trauma so intriguing

#### **circular punched out defects**

the same size as the fistula or (slightly) bigger than the fistula

#### **transverse curved defects**

bigger than the fistula whereby the fistula is somewhere within this defect

#### **quatercircular defects**

with partial or total anatomic loss of atf and atlam and possible partial loss of levator ani muscles, obturator muscles and obturator membrane

with fistula formation and possible opening of the paravesical spaces

#### **semicircular defects**

with partial or total anatomic tissue loss of atf and atlam; and with partial tissue loss of the levator ani muscles, obturator internus muscles and obturator membrane; eventually with bare bones

with fistula formation and opening of the paravesical spaces

#### **(sub)total pubocervical fascia loss**

regularly (sub)total fascia loss with extensive fistula formation and anterior vagina wall loss and total loss of atf and atlam and (partial/extensive) loss of levator ani muscles, obturator internus muscles and obturator membranes is found with bare bones in a so-called **empty pelvis**

#### **(sub)total urogenital diaphragm loss**

from time to time total loss of the whole diaphragm may be found with extensive soft tissue loss resulting in extensive urine/stool fistulas as cloaca; for these unfortunate women nothing can be done

however, anatomic tissue loss may also be found

due to **surgery** whereby tissue is excised

or due to **necrotizing infections** like postmeasles noma vaginae

## reconstructive surgery

it is important first to identify the real (extent of the) defect(s) and then reconstruct the functional anatomy meticulously using autologous structures so that normal physiology will be ensured whilst

special attention has to be given that all fascia structures are firmly (re)connected to the cervix as the centrum tendineum intrapelvinum



## discussion

the intrapelvic urogenital diaphragm as part of the corpus intrapelvinum is an important dynamic structure

it constitutes a real diaphragm with the cervix as its center with a small anterior median opening for the urethra and a larger posterior median opening for the rectum

separating the distal urinary tract and intraperitoneal contents from the distal genital tract (zero-pressure vagina) and distal digestive tract (rectum)

counteracting as first line the hydrostatic intraabdominal pressure (rise) due to the non-fatigue tonus of its smooth muscle component either by increase or relaxation under autonomic nervous coordination; the rest pressure is dealt with by the pelvis floor structures

contributing to intraabdominal compression pressure by increase in its tonus as reflex action by the sympathetic nervous system

contributing to securing and stabilizing the pelvis organs in their variable anatomic position and as such

supporting the anatomic urine and genital continence mechanisms

defects in this diaphragm are rather common and may be due to (increased) hydrostatic pressure, shearing by vaginal childbirth, pressure necrosis during prolonged obstructed labor, penetrating trauma and necrotizing infection; as also influenced by hormonal and ageing processes

depending upon (the large variety of) the anatomic location and extent of these defects the following is possible

intrinsic stress incontinence, ?cervix incompetence?, urethrocele, vesicocele, cervix prolapse and enterocele; either isolated or in combination

there is a clear correlation between genuine intrinsic urine incontinence, cystocele and cervix prolapse with a wide pubic arch of  $\geq 90^\circ$  as indication of wide pelvis

simply since the wider the pelvis the broader the span by the diaphragm and the more chance the longitudinal fibers will split/divide in the midline; with its weakest point just anteriorly from the cervix where the span is the widest

though lateral defects due to hydrostatic and/or shearing at atf level and lateral defects in the narrow triangular fascia sheath between atf and atlam are possible this will not lead to herniation of the posterior bladder wall thru these defects into the vagina

at least the author has not encountered this as the cause of cystocele; the only time the author encountered a lateral defect with cystocele formation was in a patient who developed a fourth obstetric fistula after successful repair of three previous obstetric fistulas including an extensive type **IIBb**

in quartercircular and semicircular defects with anatomic tissue loss of the intrapelvic urogenital diaphragm and with fistula formation ensuring an empty bladder, another mechanism comes into play according to the natural tissue forces

which is the opposite of what one would expect

due to the balloon-like structure of the bladder with anterior bladder wall adherent/sticking to the posterior symphysis this will result in anterior and cephalad traction onto the posterior bladder (neck) wall whereby the loose pubocervical fascia is pulled as well and will re-attach onto the posterior pubis bones and bilateral pelvis wall at a more anterior and cephalad level due to the natural tissue forces

actually, the saucer-like shape of the empty bladder in the normal anatomic situation is caused by the fact that the fixation of the posterior bladder wall onto the urogenital diaphragm prevents the natural tissue forces from adapting the posterior bladder wall onto the anterior bladder wall

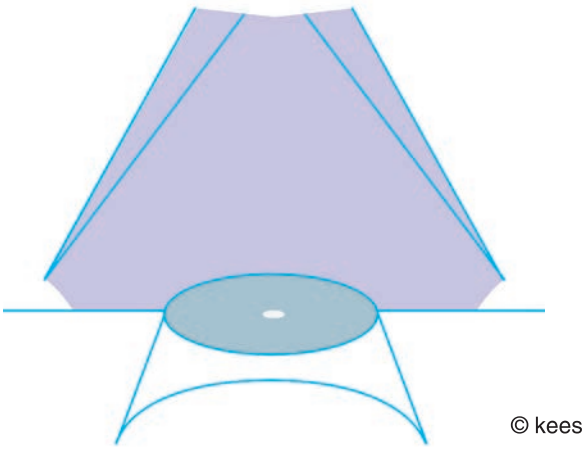


fig 45 pubocervical fascia

© kees

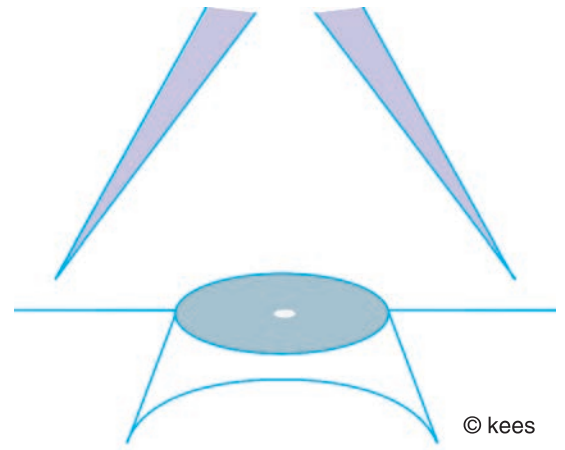


fig 46 fascia sheath atf/atlam

© kees

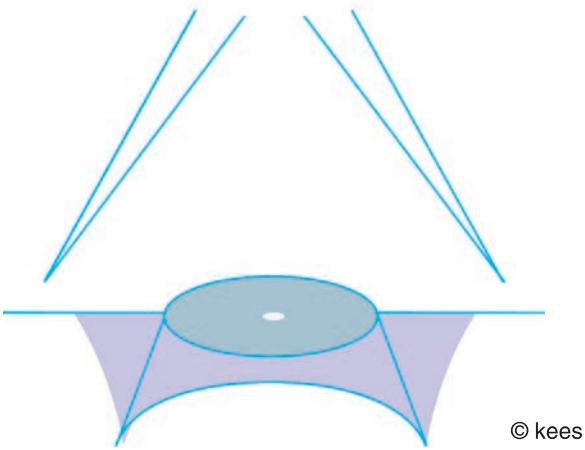


fig 47 rectovaginal fascia

© kees

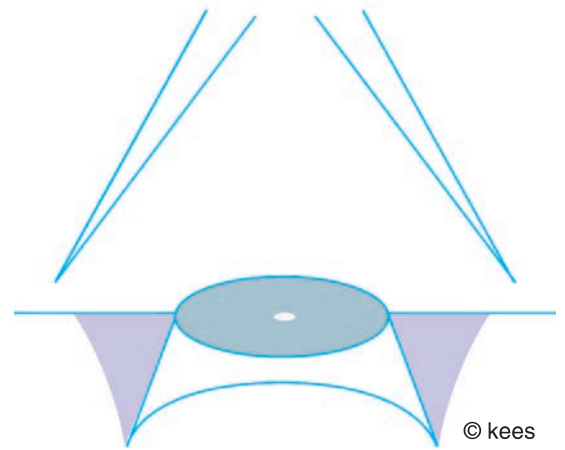


fig 48 lateral fascia attachment

© kees

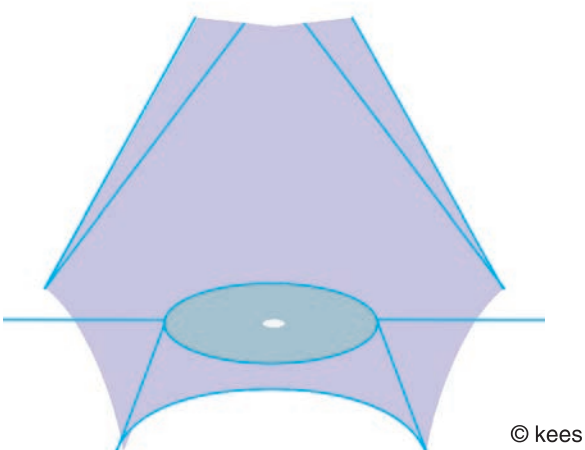


fig 49 intrapelvic urogenital diaphragm

© kees

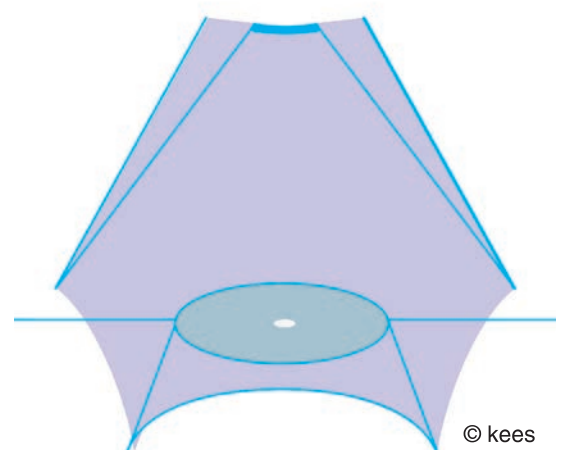


fig 50 posterior pubourethral ligaments

© kees

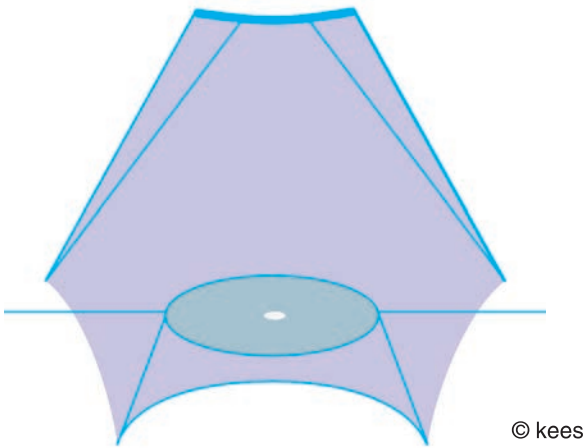


fig 51 pubovesical ligament = muscle

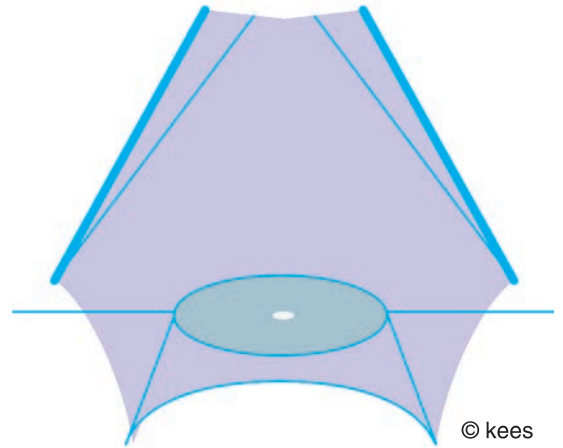


fig 52 intrapelvic urogenital diaphragm atlam

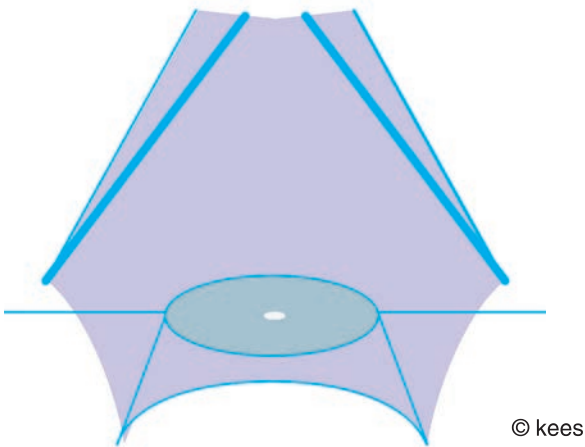


fig 53 intrapelvic urogenital diaphragm atf

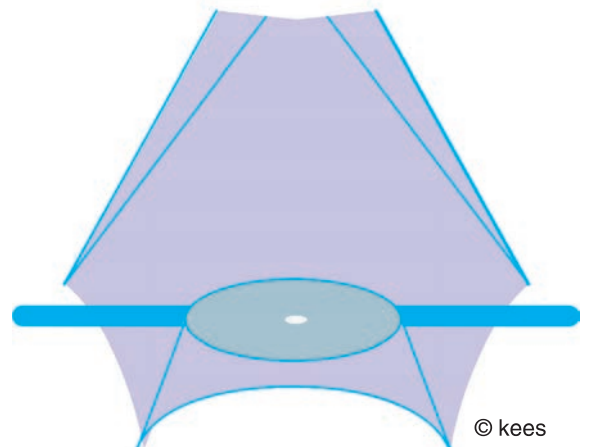


fig 54 intrapelvic urogenital diaphragm cardinal ligaments

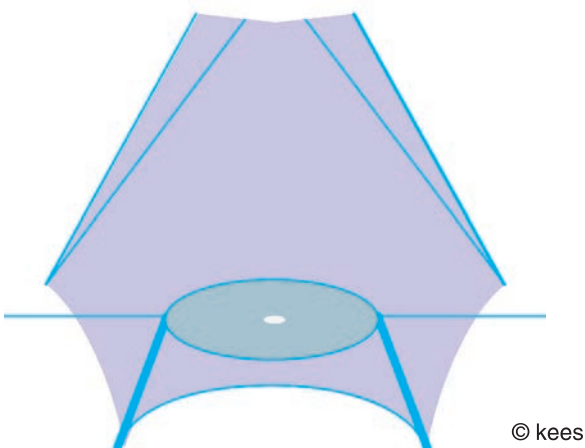


fig 55 intrapelvic urogenital diaphragm sacrouterine ligaments

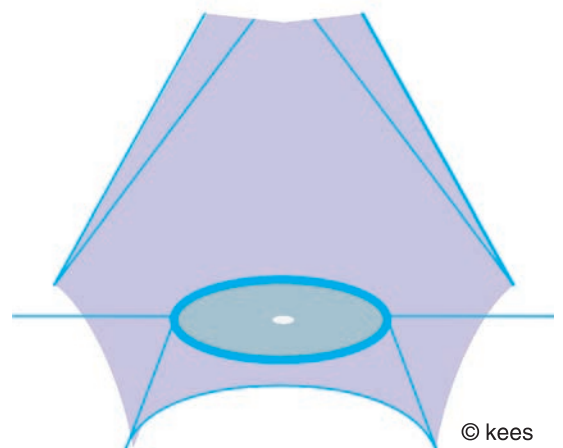


fig 56 intrapelvic urogenital diaphragm centrum tendineum intrapelvinum with fascia anchoring

# female urine continence mechanism

## introduction

the functional anatomy of the female urine continence mechanism consists of a rather complicated multi-interaction of static (bone, connective tissue) and dynamic structures (muscles; mucosa, submucous vascular plexus) and nervous innervation

the anatomic female urine mechanism comprises the bladder neck with both detrusor loops, the uv-junction and the whole urethra from internal to external opening over a total length of 4-5 cm with continence potential over its whole length as influenced by physiologic stress

there is an internal smooth muscle sphincter and an external striated muscle rhabdo sphincter with washer effect by the mucosa and submucous vascular plexus

the distal urethra and external opening are anchored into the pierced thru punched out opening in the perineum outlet diaphragm

here only a short comprehensive outline is given as a start/incentive to more extensive self-study

## functional anatomy

### anatomic urine continence mechanism

#### **bladder**

a balloon like organ for continent filling and storing of urine

the ureters, trigone and posterior urethra smooth muscles have the same origin and these structures are not as distensible as the rest of the bladder

uv-junction and stiff trigone as fixed point from which the bladder fills asymmetrically and towards which it contracts during micturition

adherent and sticking anteriorly to symphysis and (bi)laterally to pelvis wall by loose connective tissue and thin fluid film which allows friction-free upward/downward shifting/sliding of anterior and (bi)lateral bladder walls during filling and micturition

firmly adherent posteriorly to the pubocervical fascia as anterior part of the intrapelvic urogenital diaphragm

this configuration is responsible for the saucer-like shape when the bladder is empty; otherwise the posterior and anterior bladder walls would be adapted due to the natural tissue forces

anteriorly it rests upon the symphysis and posteriorly upon the pubocervical fascia as part of the intrapelvic urogenital diaphragm; in the upright position

#### **bladder neck**

two detrusor loops

trigonal ring

## **urethra**

length 3.5-4 cm

with proximal internal and distal external opening

shape and diameter

lumen

urethra mucosa

submucous vascular plexus

longitudinal smooth muscle fibers

circular/oblique smooth muscle fibers

as internal smooth muscle sphincter

elastic and connective tissue of urethra wall

horseshoe-shaped striated muscle fibers; slow-twitch and fast-twitch

as external striated “rhabdosphincter”; since posteriorly it is open and

the endings are inserting into the pubocervical fascia; so sphincter-like

## **anatomic/physiologic support**

### **symphysis pubis**

anterior bladder wall, anterior urethrovesical junction, anterior urethra are adherent/sticking to the posterior and caudad symphysis and rest upon it in the upright position

### **pubourethral ligaments: static and dynamic**

anterior and intermediate

as condensations of perineum outlet diaphragm and stabilizing the distal/mid urethra and external opening in anatomic position; since firmly anchored into this diaphragm

posterior

as condensations of the pubocervical fascia as anterior part of the intrapelvic urogenital diaphragm and stabilizing the proximal/mid urethra in its anatomic position

### **pubocervical fascia: anterior part of dynamic intrapelvic urogenital diaphragm**

in between posterior bladder/urethra wall and anterior vagina wall and from pubis bone and arcus tendineus fasciae and

from pubis bone anteriorly to cervix posteriorly and as

anterior part of the intrapelvic urogenital diaphragm in combination with cervix, broad/cardinal ligaments and parametria and sacrouterine ligaments

for stabilizing and securing the (posterior) urethra/bladder neck and cervix in their anatomic position

### **perineum outlet diaphragm**

the distal urethra with external urethra opening are anchored into the perineum outlet diaphragm

as such these structures are stabilized and secured in their anatomic position and they become part of this diaphragm whilst

contraction with increase in its tonus will support the external rhabdosphincter

no direct role of **levator ani muscles as “pelvis diaphragm”**

but only indirect role since no anatomic contact whatsoever between midline continence mechanism and lateral muscles

and anatomic continence mechanism cephalad to levator ani muscles

however, combined with the perineum outlet diaphragm together they form the

### **pelvis floor as one functional unit**

since these two structures are firmly connected to each other via the perineal body and external sphincter ani complex and so supporting and reinforcing each other

### **no support by anterior vagina wall**

very distensible and as such lacking the stiffness required; also loosely attached to and hanging on the pubocervical fascia “dragging” it down instead of pushing it up in the upright position

## intact innervation of these components

autonomic sympathetic and parasympathetic nervous system for longitudinal and circular/oblique smooth muscles; the sympathetic fibers for stimulation and continence against the parasympathetic fibers for relaxation and micturition; from hypogastric and pelvic plexus and from s2, s3, s4

the pudendal nerve innervating the external striated “sphincter” and the perineum outlet diaphragm; from s2, s3, s4

## function of anatomic structures

**the two detrusor loops** keep the bladder neck contracted during the filling phase and prevent it from opening up

**trigonal ring** keeps the urethrovesical junction contracted and prevents the internal urethra opening/proximal urethra from opening up during the filling phase

**urethra length** is normally 3.5-4 cm; the critical length for continence seems to be 1-1.5 cm; if it is shorter continence may be compromised

**urethra shape** is tube like and probably circular over its whole length since the internal opening and the external opening are circular in shape

**urethra diameter** plays a role since the more narrow the stronger the natural centripetal forces closing the urethra; physical law of Poiseuille

**urethra mucosa with submucous vascular plexus** is responsible for a water-tight closure; washer effect

**longitudinal smooth muscle layer** plays a role in micturition since by contraction of its fibers the urethra becomes shorter and wider; under autonomic nervous system control

**circular/oblique smooth muscle layer as internal sphincter** is responsible for keeping the urethra closed due to the non-fatigue tonus of its fibers; also under autonomic nervous system control

**horseshoe-shaped striated muscle layer as external “rhabdosphincter”** gives additional strength due to the tonus of its slow-twitch fibers and if needed by short-time contraction of its fast-twitch fibers; under pudendal nerve control voluntarily but also by reflex action upon intraabdominal pressure rise like coughing or standing up

**anterior, intermediate and posterior pubourethral ligaments** secure the urethra in its anatomic position anteriorly against the posterior/caudad symphysis

**pubocervical fascia as part of intrapelvic urogenital diaphragm** separates the intraperitoneal space and sub/anteroperitoneal space from the distal genital space and digestive tract; the posterior bladder, posterior urethrovesical junction and posterior urethra are adherent to it whilst an intact fascia keeps these structures in their anatomic position; if there is a defect in the fascia these structures herniate thru this defect

**anterior bladder wall, urethrovesical junction, urethra** are more or less adherent/sticking to the posterior/caudad symphysis and rest upon it in the upright position and are pressed against it; as such these structures can shift/slide friction-free against the symphysis but cannot rotate backwards away from the symphysis

**posterior bladder wall, urethrovesical junction, urethra** are adherent to the pubocervical fascia; as such these structure are mobile depending upon the movements of the fascia; if the support becomes defective they can rotate backwards away from the symphysis causing funnelling of the proximal or total urethra

**anterior vagina wall** is loosely adherent to the pubocervical fascia; with circular ruga folds of the vagina due to natural tissue forces; it lacks the stiffness characteristics required for support of the anatomic urine continence mechanism

**pubococcygeus muscles as part of levator ani muscles** on contraction will squeeze the posterior and bilateral vagina walls resulting **indirectly** into cephalad and anterior movement of anterior vagina wall with adherent pubocervical fascia for a better support of the posterior bladder neck, urethrovesical junction and urethra; and as such contribute to a better configuration of the anatomic continence mechanism

**other pelvis floor structures of the perineum outlet diaphragm** play a **direct** role in stabilizing the distal/mid female urethra in its anatomic position since these organs with the external “rhabdo” sphincter are anchored into the perineum outlet diaphragm

**intact innervation of these components** is needed for smooth coordination of all the physiologic processes

## physiology of continence and micturition

the literature is so abundant and confusing and contradicting that it is not possible to study it all and produce an evidence-based true statement; see chapter: **remarks on urine continence mechanism**

### **basic continence principles**

movement of contents within an organ is only possible from higher pressure levels towards lower pressure levels

so as long as the urethra closing pressure is higher than the intravesical excretory pressure there is continence



as soon as the intravesical pressure becomes higher than the urethra closing pressure urine will flow thru the urethra towards the outside; either as voluntary physiologic action like during micturition or involuntarily and then it is called incontinence

### **urethra closure**

it is not clear whether urethra closure is **circular** (external and internal opening circular on direct inspection) **or** that it is by **coaptation**;

however, if it is by coaptation then coaptation of the **posterior** urethra wall **against** the **anterior** urethra wall since **immobile anterior** bladder neck/uv-junction/urethra are more or less fixed/adhesive to and pressed against symphysis whilst **mobile posterior** bladder neck/uv-junction/urethra are adherent to elastic pubocervical fascia

### **biophysiomechanics**

the two detrusor loops and trigonal ring keep the urethrovesical junction closed during the filling phase of the bladder

the urethra is kept closed/adapted by centripetal forces and by the tonus of the internal sphincter and slow-twitch fibers of the external “sphincter”; whilst the urethra mucosa and submucous vascular plexus are responsible for a water-tight urine seal

during the compliant filling phase of the bladder these mechanisms maintain closure of urethrovesical junction and (proximal) urethra; when the bladder fills up more these forces increase via impulses from baroreceptors

(voluntary) increase of these forces is possible directly by contraction of the external urethra “rhabdosphincter” and (in)directly by contraction of the pelvis floor muscles; with increase in the tonus of the smooth muscles of the intrapelvic urogenital diaphragm by reflex action of the sympathetic nervous system

at sudden intraabdominal pressure rise there is a reflex increase in tonus of the smooth muscle fibers of the intrapelvic urogenital diaphragm and contraction of the external urethra “rhabdosphincter” which takes place a few milliseconds before there is an increase in intravesical pressure since first the thoracic diaphragm and the anterior abdominal musculature contract (with or without contraction of the pelvis floor) on cough and this causes intraabdominal pressure rise a few milliseconds later; this action may be reinforced directly and indirectly by simultaneous reflex contraction of the pelvis floor muscles

if these **intrinsic** mechanisms are deficient, for whatever reason, stress incontinence develops in varying degrees

at the beginning of voluntary micturition the two detrusor loops relax whilst the longitudinal detrusor muscle contracts with additional relaxation of the detrusor loops, the fast-twitch and slow-twitch muscle fibers of the external urethra “rhabdosphincter” relax, the pelvis floor muscles relax, the tonus of the intrapelvic urogenital diaphragm relaxes, the longitudinal smooth musculature of the urethra contracts whilst the circular smooth muscle fibers as internal sphincter relax resulting in urethra shortening with an increase in its diameter

so, the forces which close the urethra decrease whilst intravesical pressure increases and the urethra opens up from proximally, from the urethrovesical junction, towards distally, towards the external urethra opening, and stays open during micturition

at the end of spontaneous micturition the opposite takes place and the urethra stretches with a decrease in its diameter

so, the forces which close the urethra increase whilst intravesical pressure decreases and the urethra closes

## pressure transmission on sudden intraabdominal pressure rise

there is pressure transmission on sudden (or slow) increase in intraabdominal pressure due to cough, standing up, straining etc

its net effect upon the cephalad/anterior and caudad/posterior movement of the pubo cervical fascia as anterior part of the intrapelvic urogenital diaphragm will determine if this has a positive, neutral or negative effect on keeping the urethra closed

on cough by contraction of thoracic diaphragm and abdominal musculature without simultaneous contraction by pelvis floor the pressure transmission will be coming from cephalad and anteriorly

and will reach the bladder first before pushing down on the intrapelvic urogenital diaphragm despite reflex increase in its tonus; and only if defective this will result in backwards rotation of the posterior urethra wall away from the symphysis and will have a negative effect

on cough by contraction of thoracic diaphragm and abdominal musculature and with simultaneous contraction by pelvis floor the pressure transmission will be from cephalad, from anteriorly and from caudad simultaneously

since the distance from the pelvis floor to the intrapelvic urogenital diaphragm is shorter than the distance from the thoracic diaphragm the caudad pressure will first reach the urogenital diaphragm and move this anterior/cephalad before meeting the anterior and cephalad pressure; this will result in rotation of the posterior urethra wall forwards toward the symphysis and will have a positive effect

if the pelvis floor contracts earlier than the thoracic diaphragm and anterior abdominal musculature the positive effect will be strengthened

however, the ultimate effect, involuntary urine loss or continence, is with the intrinsic forces of the continence mechanism

## anatomic changes at urethrovesical junction and urethra

### **vesicalization**

funneling of the internal urethra opening and proximal urethra may occur and this is called vesicalization by heinrich martius since this part of the urethra becomes part of the bladder (vesica); it may be partial or total

### **re-urethralization**

by tightening the support the vesicalized urethra becomes again proximal urethra so this is called by the author re-urethralization

### **urethralization**

in post-fistula repair intrinsic incontinence with real circumferential loss of the proximal urethra the remaining bladder neck can be narrowed by special operation technique and function as the proximal urethra; this is called urethralization by the author

## **stress incontinence mechanism**

the anterior urethra wall is adherent to the posterior symphysis by loose connective tissue and a thin fluid film which allows the anterior urethra wall to shift against the symphysis friction free, though little; however it cannot rotate backwards away from the symphysis

the posterior urethra wall is firmly adherent to the pubocervical fascia with pubourethral ligaments as part of the intrapelvic urogenital diaphragm

if defects develop within this diaphragm the posterior urethra wall will rotate backwards away from the symphysis causing partial (or total) funneling of the proximal (or total) urethra since the anterior urethra wall stays sticking against the symphysis; this process is called vesicalization since functionally the funneled part of the urethra becomes part of the bladder (vesica)

besides backward rotation there is also backward shifting of the posterior urethra wall against the anterior urethra wall into the direction of the sacrum; since the anterior external opening is fixed and immobile

these two mechanisms of pathophysiologic action result into a wider (proximal) urethra lumen and a more oval elliptical arrangement of the smooth muscle fibers and

interfere with the intrinsic forces keeping the urethra closed since more force is needed to close the urethra; less resistance according to Poiseuille law

once the intrinsic forces can no longer keep the urethra closed sufficiently this will lead to genuine or post fistula repair intrinsic stress incontinence in various degrees

in total intrinsic stress incontinence there is continuous leaking of urine on lying/sitting/standing/walking due to total loss of the intrinsic forces

intraoperatively under spinal anesthesia in these patients in the exaggerated lithotomy position the level of urine within the urethra is noticed in concord with respiration, rising on expiration and lowering on inspiration

a third mechanism may be a defect in the anchoring of the distal urethra (with external urethra opening) into the perineum outlet diaphragm; with or without avulsion

this mechanism is probably responsible for the development of postpartum genuine intrinsic stress urine incontinence with hourglass or sandglass deformity of the urethra which is rather common; though combined with a median longitudinal defect within the pubocervical fascia as part of the intrapelvic urogenital diaphragm

## urge incontinence mechanism

in urge incontinence there are involuntary contractions of the detrusor muscle without reflex increase in the intrinsic closing forces setting involuntary micturition in motion whilst voluntary increase in the extrinsic forces is too weak and too short to stop the involuntary micturition

the involuntary contractions are triggered by low-threshold pacemaker, irritation of the pacemaker (like in cystitis) or by an ectopic pacemaker?

## discussion

the author outlines the various structures and factors which influence the functional anatomic urine continence mechanism in the female

it is up to the reader to make his/her own conclusions

# intraabdominopelvic pressure dynamics

## consequences for continence

### introduction

movement of contents within an organ is due to intraluminal pressure differences from higher towards lower pressure

(in)continence is based upon pressure differences between proximal intraluminal excretion pressure and distal closing pressure by the continence mechanism

as long as the distal closing pressure is higher than the proximal excretion pressure there is continence

once the proximal excretion pressure becomes higher than the distal closing pressure the contents will move towards the outside

there are three important physical laws which have to be considered:

### law of pascal

pressure exerted anywhere on an incompressible fluid in a confined space is transmitted equally in all directions throughout the fluid such that the pressure variations (initial differences) remain the same

### law of laplace

in cylindrical structures (like urethra and anorectum)

wall tension = intraluminal pressure x radius

or intraluminal pressure = wall tension divided by radius

in spherical structures (like bladder and rectum ampulla)

wall tension = intraluminal pressure x radius divided by 2

or intraluminal pressure = wall tension x 2 divided by radius

### law of poiseuille

in laminary flow in a tube like structure like the urethra, resistance is directly related to the 4th power of the radius; the smaller the diameter the higher the resistance

there is hydrostatic pressure depending upon the vertical height of the filling content and there is compression pressure by the wall; the highest pressure is at the lowest point

the intraluminal pressure is influenced by filling of the organ (with increase in hydrostatic pressure at lowest point) and the (resulting) tonus of the organ wall; the tonus of the organ wall may be increased by active contraction

the final resulting intraluminal pressure at a certain point is the sum of the intraluminal hydrostatic pressure + compression pressure

then there is overall atmospheric pressure

## **intraabdominopelvic pressure**

the abdominopelvic cavity is enclosed by the diaphragm cephalad, the anterior abdominal wall anteriorly, the lateral abdominal walls laterally, the spine with trunk muscles and sacrum posteriorly and the pelvis floor and coccyx/sacrum caudad

the abdominopelvic cavity can be divided into 5 different spaces

intraperitoneal space	its own entity
retroperitoneal space	its own entity
pre/subperitoneal bladder space	its own cavity
subdiaphragmatic space	its own cavity
subfascial space	its own cavity

it is important to have an idea about the differences in pressure within the abdominopelvic cavity as a whole, within the 5 different spaces and within the organs

there is hydrostatic pressure due to the weight of the contents and additionally there is compression pressure due to the tonus of and upon contraction of thoracic diaphragm, abdominal musculature and pelvis floor musculature

these two pressures work upon all the intraabdominopelvic organs

then there are compression pressures within the 5 different spaces only for that specific individual space which may or may not be transmitted to the other spaces

during inspiration there is a reduction in compression pressure whilst during expiration there is increase in compression pressure; since the abdominal wall and intrapelvic urogenital diaphragm are mobile they will move

and there is pressure by the filling rate of the individual organs and contraction/tonus of these organ walls

the individual organs are (in)directly fixed to the abdominopelvic walls by connective tissue or ligaments; then they lie upon each other

in the male in the upright position the intraperitoneal organs rest upon the pelvis floor, coccyx and sacrum

in the female the pre/subperitoneal organs and the intraperitoneal organs rest first upon the intrapelvic urogenital diaphragm

this diaphragm is the first structure resisting/counteracting the hydrostatic pressure and compression pressure in the intraperitoneal and pre/subperitoneal spaces

## **intraabdominopelvic pressure rise**

during cough with forceful contraction of thoracic diaphragm and abdominal musculature the resulting intraabdominal pressure pulse will be from cephalad and anteriorly towards posteriorly and caudad

since the spine with trunk muscles are immobile the result will be that the mobile intrapelvic urogenital diaphragm will move caudad with negative effect upon the female urine

continence mechanism though with reflex contractions of the smooth and striated urethra musculature

and increase in tonus of the intrapelvic urogenital diaphragm and of the pelvis floor

if on cough the pelvis floor muscles are contracting as well then the pressure wave moves simultaneously from caudad, anteriorly and cephalad towards posteriorly without downwards movement of pubocervical fascia

if the pelvis floor muscles contract just before cough then the pubocervical fascia moves cephalad and will be stabilized since the pressure wave first moves from caudad with anterior/cephalad movement of the pubocervical fascia and then is joined by pressure waves from anteriorly and cephalad which will only result in a higher intraabdomino pelvic pressure

### **intravesical pressure**

inside the bladder there is hydrostatic pressure combined with intraluminal compression pressure

in the standing position the hydrostatic pressure (due to intraabdominal + intravesical content combined) is highest on the uv-junction since that is the lowest point

in sitting, squatting and lying down the highest hydrostatic pressure changes to the lowest point which is no longer the uv-junction but changes over the bladder base towards the cervix since on lying the cervix is the lowest point whilst the vertical diameter of the bladder changes and becomes less so the hydrostatic pressure at the lowest point becomes less but also on the uv-junction

in lying the hydrostatic static pressure only depends upon intravesical content

if the intrinsic forces within the urethra are functioning well there will be full continence in walking, standing, sitting, squatting and lying and on sudden intraabdominal pressure rise like coughing or standing up

if the intrinsic forces become insufficient at a certain point there will be intrinsic stress incontinence depending upon the residual strength of the intrinsic forces

first grade I only involuntary urine loss whilst standing up and/or cough in standing

then grade II also involuntary urine loss on standing/sitting with and/or without cough

then grade III more or less continuous urine loss whilst lying/sitting/standing/walking with and without spontaneous miction

genuine or postrepair stress incontinence is always an expression of a deficient intrinsic closing/continence mechanism

by reinforcement/reconstruction of the anatomic continence mechanism intrinsic stress incontinence will disappear

### **short-term reinforcement of continence mechanisms**

if there is an urge to urinate or to defecate this may be counteracted by contraction of the pelvis floor muscles with anterior/cephalad movement of the pubocervical fascia and by contraction of the striated sphincters

and increase in tonus of the intrapelvic urogenital diaphragm by reflex action

### **multiple sheet architecture counterbalancing intraabdominal hydrostatic pressure**

the intrapelvic urogenital diaphragm is the main force in counteracting the intraabdominal hydrostatic pressure; in combination with parietal peritoneum, bladder dome wall (+ visceral fascia) and uterus, posterior bladder wall (+visceral fascia) and cervix and anterior vagina wall (+ visceral fascia); overlying "closing"

the large opening in the "pelvis diaphragm" and large vagina opening in the perineum outlet diaphragm

to this comes as secondary help the "pelvis diaphragm" and perineum outlet diaphragm as dynamic pelvis floor

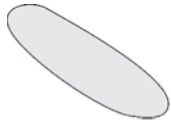
### **references**

law of pascal

law of laplace

law of poiseuille





© kees

fig 57

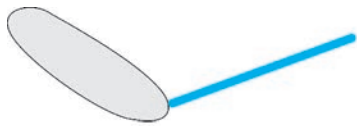
symphysis



© kees

fig 58

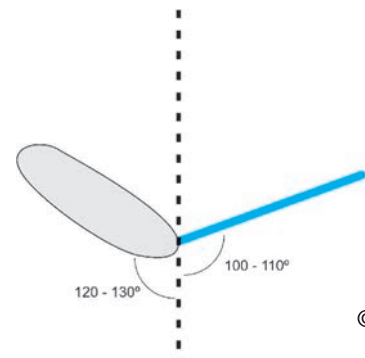
pubocervical fascia



© kees

fig 59

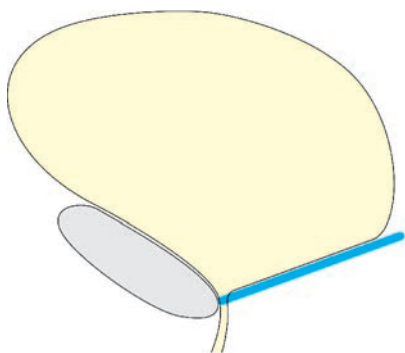
symphysis + pubocervical fascia



© kees

fig 60

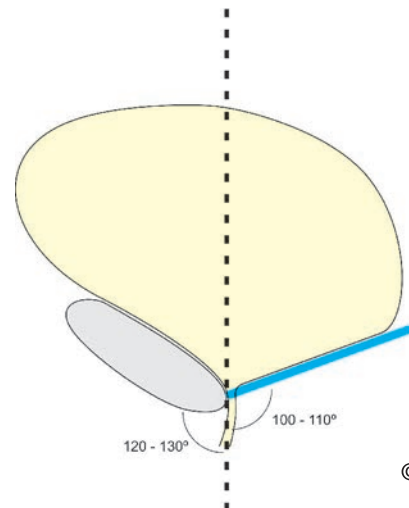
symphysis + pubocervical fascia



© kees

fig 61

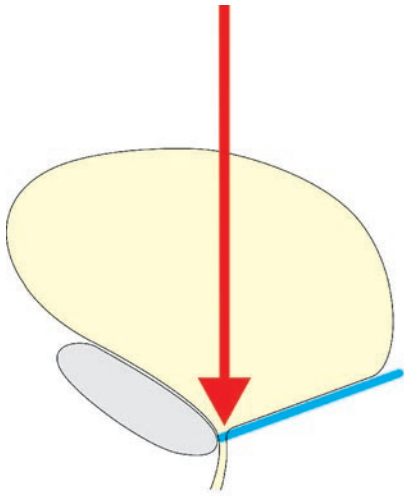
bladder resting upon  
symphysis + pubocervical fascia



© kees

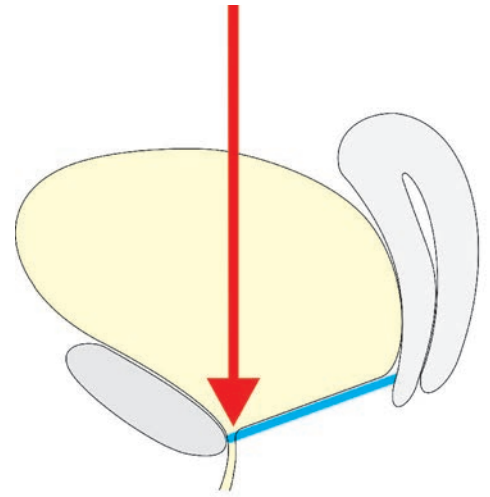
fig 62

bladder resting upon  
symphysis + pubocervical fascia



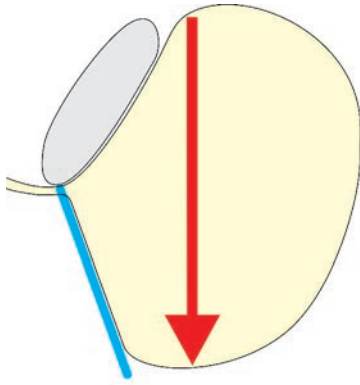
© kees

fig 63 intraabdominal + intravesical hydrostatic pressure upright position



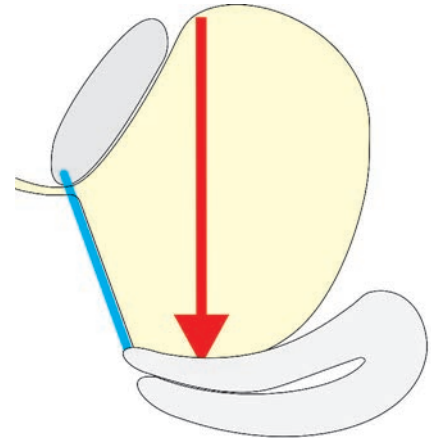
© kees

fig 64 intraabdominal + intravesical hydrostatic pressure upright position



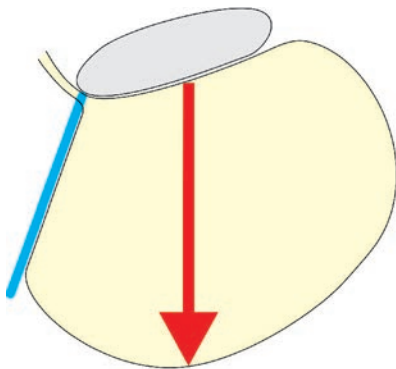
© kees

fig 65 only intravesical hydrostatic pressure lying position



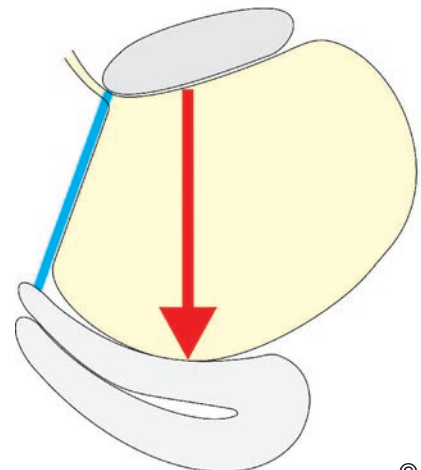
© kees

fig 66 only intravesical hydrostatic pressure lying position



© kees

fig 67 only intravesical hydrostatic pressure exaggerated lithotomy position



© kees

fig 68 only intravesical hydrostatic pressure exaggerated lithotomy position

# remarks female urine continence mechanism

## introduction

the author is privileged to see and study the experiments of nature about the urine continence mechanism in the female as presented by the complex obstetric trauma

his findings of anatomic tissue loss, physiologic operation techniques to step-by-step reconstruct the functional anatomy, evidence-based results and resulting theory are in sharp contrast with the various theories about the urine continence mechanism in the female

## remarks

### mid-urethra as decisive factor/distal urethra negligible

the concept of the middle third urethra being the decisive factor in continence seems to be incorrect since

several patients with total circumferential urethra loss type **IIBb** have already full continence after circumferential fixation with rhaphy of the bladder neck into anatomic position of euo as first stage and do not need urethra reconstruction as planned second stage if the pubocervical fascia is refixed as well anatomically correct and bilaterally onto the symphysis and arcus tendineus fasciae

more than 90% of the patients with circumferential anatomic loss of uv-junction/proximal/mid urethra type **IIAb** have full continence after circumferential end-to-end vesicourethrostomy even with (distal) urethra length of only 1-1.5 cm

the majority of patients with total 3° cervix prolapse are totally continent even with urethra length of only 0.5-1 cm and even after reduction not due to kinking (which is not possible anatomically) but due to narrowing of the distal urethra/euo under physiologic stress with an increase in resistance

preservation of distal urethra with external opening (even if only 0.1 cm left) will contribute to full post fistula repair continence as based on evidence

patients with distal urethra trauma due to yankan gishiri come forward for repair since they complain about continuous urine leakage; once a continent distal urethra reconstruction has been performed they are continent

patients in whom the anchoring of the distal urethra and its external opening has been traumatized, with or without avulsion, are totally incontinent but will regain full continence once the functional anatomy been reconstructed

## **closure of the urethra: circular or by coaptation**

on clinical examination both the external opening (inspected from the outside) and the internal opening (inspected from the inside during fistula repair) are **circular** and not horizontally flat; the external opening may even be like a vertical slit

if the urethra closes by coaptation and not circularly (which is very well possible though why should the internal/external openings then be circular) it must be coaptation of the **mobile** posterior urethra wall onto the **fixed** anterior urethra wall

## **pubocervical fascia/anterior vagina wall as backstop**

the notion that the pubocervical fascia with anterior vagina wall functions as a backstop does not make sense since

how could the fixed/adhesive immobile anterior bladder wall/uv-junction/urethra wall be compressed against the mobile fascia

is it not more logical that the mobile fascia with adherent posterior bladder neck/uv-junction/urethra wall is compressed against the fixed (onto symphysis) anterior bladder neck/uv-junction/urethra wall

so if coaptation it must be posterior onto anterior

## **anterior to posterior coaptation**

see previous argument

## **anterior vagina wall as hammock**

the vagina (wall + fascia) is very distensible and as such lacks the stiffness characteristics required to support the intrapelvic urogenital diaphragm with adherent posterior bladder neck/urethra

actually, the anterior vagina wall is hanging onto the intrapelvic urogenital diaphragm dragging it down instead of pushing it up

the vagina is a low- or zero-pressure organs since normally there is no filling content; as such it cannot support the posterior bladder neck/urethra by its “missing contents”

## **intrapelvic urogenital diahragm**

the intrapelvic urogenital diaphragm is not a hammock with a two-point lateral fixation which would allow rather large anterior forward/posterior backward swing movements with traction onto posterior urethra wall but

as a **drum-skin-like or trampoline diaphragm** there is circumferential fixation onto the pelvis wall with only slight cephalad/caudad movement with almost no traction onto the posterior urethra wall

securing/stabilizing the posterior bladder base wall, posterior uv-junction and posterior urethra wall in their anatomic position

## **pressure transmission**

pressure transmission from where to where since pressure exerted upon a fluid is evenly distributed into all directions (physical law of pascal)

how then can the pressure rise wave from anterior/cephalad first reach the urethra before it reaches the bladder

how can pressure rise transmission with the tendency to open the urethra since rise in intravesical pressure now be involved in closure of the urethra especially since

the pressure rise wave will press the anterior urethra wall firmer against the symphysis whilst it may push the posterior urethra wall away from the symphysis against the pubo cervical fascia as anterior part of the intrapelvic urogenital diaphragm

the increase in urethra closure pressure as noted during urodynamics is probably due to an increase in tonus of the dynamic smooth muscle intrapelvic urogenital diaphragm by reflex action of the sympathetic nervous system

## **position of urethra with regards to pressure transmission**

if the urethra is positioned intraabdominally pressure transmission has a positive effect whilst if the urethra is positioned intrapelvically pressure transmission has a negative effect; this does not make sense

first of all, the urethra is always situated intrapelvically however cephalad to the intra pelvic urogenital diaphragm and never intraabdominally

second, even if it would be situated intraabdominally how now could pressure transmission in the abdominal position have a positive effect on the continence mechanism and in the pelvic position a negative effect

## **pelvis floor muscle exercises**

the paramount role of the levator ani muscles in the urine continence mechanism can not be confirmed since there is nowhere direct anatomic contact between the midline continence mechanism and the lateral levator ani muscles

and the whole urinary tract including the urine continence mechanism is cephalad to the levator ani musculature

however, pelvis floor (levator ani + perineum) muscle exercises have a positive effect on the urine continence mechanism by an **indirect** action of the levator ani muscles and a **direct** action by perineum outlet diaphragm; as one functional unit

see mechanism of pelvis floor muscle exercises

## **external rhabdosphincter + compressor urethrae + urethrovaginalis muscles**

though there is a striated muscle sphincter, the author has difficulties in understanding/ accepting the anatomic arrangement that

this complex is proximally first horseshoe shaped around anterolateral urethra inserting into intrapelvic urogenital diaphragm

then more distally and ventrally from this diaphragm becomes bow like from ischiopubic rami "around" anterior urethra and

then even more distally becomes circumferential around anterolateral urethra and vagina combined

also as separate muscles this would be a strange functional anatomic arrangement; so do these muscles exist and if so do they function as described

### **urethra length and diameter**

an effort has to be made to preserve as much of the urethra as possible during fistula repair; also an effort has to be made of reducing a wide external opening/distal urethra to a normal diameter

### **kinking of the urethra in total 3° cervix prolapse**

is anatomically not possible since the anterior bladder neck/uv-junction/urethra are firmly attached/sticking to the symphysis by loose connective tissue and a thin fluid film and in the upright position firmly pressed against the symphysis by gravity and the abdominal contents

kinking would mean that the anterior bladder neck/uv-junction/urethra would become loose from the posterior symphysis and by what kind of tissue/air/fluid would that space be filled since there cannot be empty spaces within the body mass

### **masked incontinence in total 3° cervix prolapse**

the norm is full continence even after reduction of the prolapse; only **over-correction** resulting into traction onto the posterior urethra wall may provoke the so-called masked incontinence

### **integral theory**

the author cannot comprehend this theory and does not understand the use of synthetic allograft material to reconstruct the functional anatomy instead of using the available dynamic autologous structures

unless there is a financial conflict of interest to support the multibillion-dollar medical industry

### **separate fibers of the levator ani musculature**

it is understandable that fibers of the puborectalis part of the levator ani muscles radiate into the deep portion of the external sphincter ani muscle

however, since the levator muscles are inside a fibrous compartment as encapsulated by a striated muscle fascia originating from the arcus tendineus levatoris ani (superior and inferior pelvis diaphragm fascia)

how is it then possible that some fibers pierce thru this fascia and meet with fibers from the other side thru the tela urogenitalis

so if there are striated muscle elements these must be originating from and related to the striated sphincter muscle structures as anchored inside the perineum as outlet diaphragm

as well the author was never able to identify striated muscle fibers crossing the midline caudad from the posterior urethra wall or cephalad to the anterior (ano)rectum wall

### **trauma to levator ani muscles due to hydrostatic pressure**

since it does not constitute a real diaphragm and it is the second line of coping with the rest hydrostatic pressure this is minimal, even during pregnancy

### **trauma to levator ani muscles during childbirth**

considering their topographic position the levator ani muscles are well protected against the physiologic obstetric trauma during normal vaginal childbirth

however, theoretically their origin at the atlam may sustain slight trauma due to shearing during passage of the head of the infant thru the vagina

and the opening between the puborectalis ledges will be dilated as will the levator plate otherwise the head could not pass; but these structures are well primed by the flooding of hormones during pregnancy

the author never identified specific lesions at the levator ledges or plate though there may be laxity of the muscle as a whole

if the introitus becomes too wide it is more due to trauma to the perineal body than due to trauma to the levator ani muscles

whilst trauma to the special levator nerve is possible but difficult to detect

only during prolonged obstructed labor their origin at atlam + the cephalad part of the levator ani muscles may become affected by pressure necrosis as frequently noted by the author in the circumferential obstetric fistulas type **IIAb** and **IIBb**

### **ageing trauma to levator ani muscles**

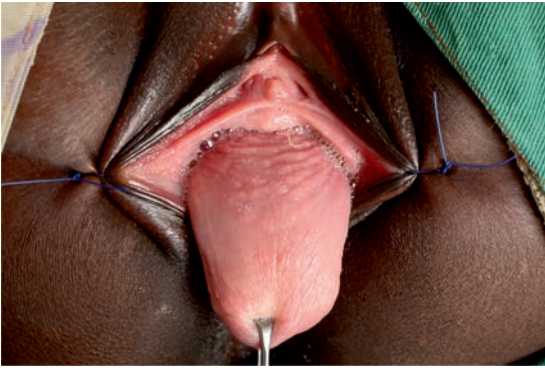this is very well possible but will not have any effect upon the anatomic urine continence mechanism or the development of prolapse

### **urodynamics**

are we treating the machine or are we treating the patient

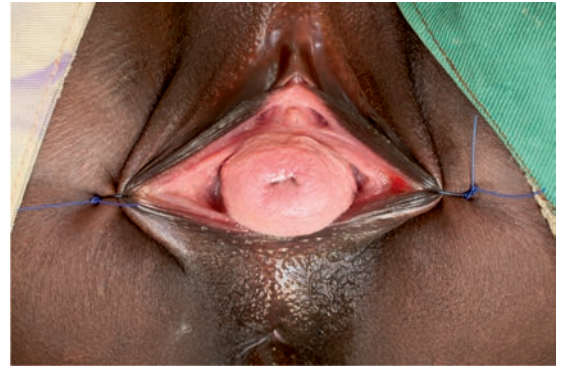### **discussion**

another concept is needed



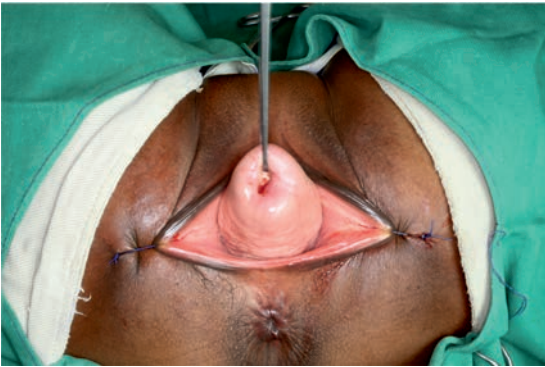© kees

fig 69 total cervix prolapse



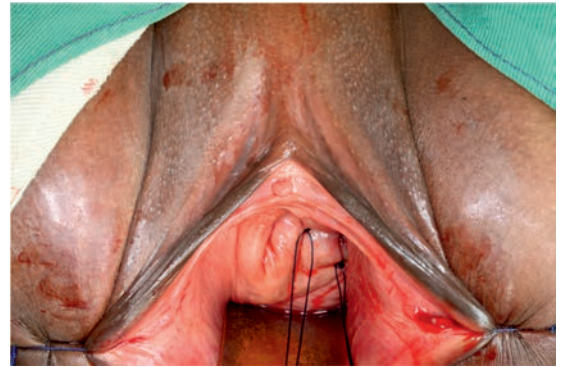
© kees

fig 70 narrow euo



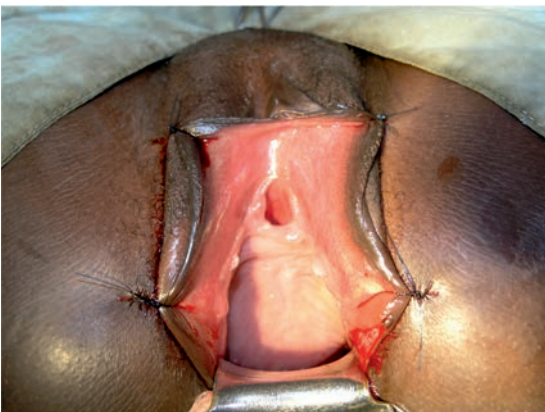
© kees

fig 71 total cervix prolapse



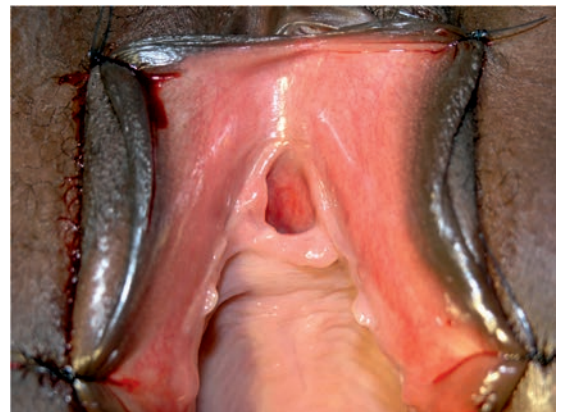
© kees

fig 72 narrow euo after cervix fixation



© kees

fig 73 deformed euo anchoring trauma



© kees

fig 74 detail euo



# female stool continence mechanism

## functional anatomy

### introduction

the functional anatomy of the female stool continence mechanism consists of a rather complicated multi-interaction of static (connective tissue) and dynamic structures (muscles, mucosa, submucous vascular plexus) and nervous innervation

the anatomic stool continence mechanism is situated within the distal 4-5 cm of the anorectum, the external sphincter ani muscle and support

there is an internal smooth muscle sphincter and an external striated muscle sphincter with washer effect by the mucosa and submucous vascular plexus

the distal anorectum and external sphincter ani are anchored into the pierced thru punched out opening in the perineum outlet diaphragm

here only a short comprehensive outline is given as a start/incentive to more extensive self-study

### functional anatomy

#### anatomic stool continence mechanism

##### **anorectum-rectum junction**

diameter

anorectal angle, normally 80°-100°

##### **anorectum**

length 4-5 cm

shape and diameter

lumen

anus mucosa

anal cushions = columnae anales

submucous vascular plexus

circular smooth muscle fibers = internal sphincter ani

longitudinal smooth muscle fibers

##### **sphincter ani muscle**

circular striated muscle fibers around distal anorectum/anus

consisting of mostly slow-twitch for tonus but also fast-twitch for emergency closure

divided into three parts:

subcutaneous

superficial

deep

## anatomic/physiologic support

### **rectovaginal or prerectal fascia** (of denonvillier)

supports the anterior anorectum

### **perineum outlet diaphragm**

the anorectum with external sphincter ani complex are firmly anchored into the pierced thru punched out opening within the perineum outlet diaphragm

### **perineal body (= centrum tendineum perinei) with transversus perinei and bulbo spongiosus muscles**

stabilizes the anus and sphincter ani anteriorly and laterally; in a way that is comparable to the role of the pubocervical fascia in stabilizing the posterior urethra

### **anococcygeal ligament**

stabilizes the anus posteriorly

### **levator ani muscles + levator plate**

anterobilaterally from pubis bone and arcus tendineus levator ani as a sling around the lateral and posterior anorectum walls and external sphincter ani, and inserting into levator plate, anococcygeal ligament and coccyx

especially the puborectalis muscles, median part of pubococcygeus muscles, play a role pulling the anorectum anteriorly; these muscles are responsible for the anorectal angle; its fibers fuse with the deep portion of the external sphincter ani muscle

### **posterior vagina wall**

attached to perineal body and rectovaginal or pre(ano)rectal fascia and rectum serosa

### **perianal skin with subcutaneous tissue and constrictor ani muscle**

stabilizes also the anus/sphincter ani muscle

## intact innervation of these components

autonomic sympathetic and parasympathetic (vagus) nervous system for the circular smooth muscle as internal sphincter and longitudinal smooth muscle; the sympathetic fibers for stimulation and continence against the parasympathetic fibers for relaxation and defecation; from hypogastric and pelvic plexus

puddental nerve innervating the external sphincter ani; from s2, s3, s4

levator ani nerve innervating levator ani muscles; from s3, s4

## discussion

the stool continence mechanism must take care of

### **gas**

for final sealing off the mucosa with mucosa cushions and the submucous vascular plexus are responsible

### **liquid stool**

for final sealing off also the mucosa with mucosa cushions and the submucous vascular plexus are responsible

### **solid stool**

this is the easiest since normally there is no stool inside the rectum

**anorectal angle** is determined by the puborectalis muscle and is normally 80°-100°; if it contracts the angle will become sharper; however, this seems to be of minor importance

**anorectum mucosa with mucosa cushions and submucous vascular plexus** are responsible for air- and water-tight closure; washer effect

water-tight closure is a problem since liquid stool inside the rectum is accompanied by a strong urge component with bowel contractions

linea dentata between squamous epithelium (proctodaeum origin) with sensibility for pain and touch since innervated by pudendal nerve and cubical epithelium (hindgut origin) without sensibility since innervated by autonomic nervous system

**thickened circular smooth muscle = internal sphincter ani** is the strongest factor and responsible for closure due to non-fatigue tonus; it is separated from the external sphincter by the longitudinal smooth muscle layer sheath

**longitudinal smooth muscle** is playing a role in defecation since it will shorten the anorectum if contracting; it separates the internal sphincter ani muscle from the external sphincter ani muscle

**rectovaginal or prerectal fascia (denonvillier)** bilaterally from an arcus tendineus attached to levator ani muscle fascia; this is attached to/supporting the anterior ano rectum; if defective a rectocele will develop

**external sphincter ani** circular around the distal anorectum and consists of striated muscle fibers; the slow-twitch muscle fibers are contributing to its tonus whilst the fast-twitch fibers will contribute to short-duration closure of the anus; especially in the female it is thicker posteriorly than anteriorly

it consists of 3 parts: subcutaneous, superficial and deep; fibers of the puborectalis muscle fuse with the deep part bilaterally and posteriorly

it is separated from the internal sphincter by the longitudinal smooth muscle sheath of the anorectum

the external sphincter extends 0.5-1 cm distally from the internal sphincter (intersphincteric groove) and protrudes slightly from the surrounding skin

### **perineum outlet diaphragm**

the anorectum with the external sphincter ani complex are firmly anchored into the pierced thru punched out opening within this diaphragm stabilizing/securing these structures in their anatomic position

active contraction of its striated muscle component and reflex contraction of its smooth muscle component will reinforce the stool continence mechanism

### **perineal body**

wedge-like connective tissue structure into which the bulbospongiosus and transversus perinei muscles radiate; attached to anterior external sphincter ani

this structure stabilizes and secures the anterior sphincter ani/anorectum in its anatomic position and as such supports the stool continence mechanism

### **transversus perinei muscles**

bilaterally from ischial tuberosity and uniting indirectly medially via the perineal body and prevent lateral shifting of perineal body/anus

### **bulbospongiosus muscles**

bilaterally from paraclitoridally and uniting posteriorly medially via the perineal body and prevent posterior shifting of perineal body/anus

### **levator ani muscles + levator plate**

a flat striated muscle sheath originating anterobilaterally from pubis bone and arcus tendineus of levator ani muscles (atflam) and like a sling around lateral vagina walls and laterally from and underneath sphincter ani/anorectum/rectum and fusing with each other and inserting posteriorly from sphincter ani/anorectum/rectum into levator ani plate, anococcygeal ligament and coccyx bone

it consists of 3 parts based on their origin: pubococcygeus, iliococcygeus and (ischio) coccygeus (?sacrospinous ligament?)

the medial part of the pubococcygeus is called the puborectalis muscle; this portion fuses with the bilateral and posterior deep external sphincter ani muscle fibers; it is responsible for the anorectal angle

for some investigators the (ischio)coccygeous muscle is (synonymous with) the sacrospinous ligament

due to its sling-like shape contraction of the levator ani muscles compresses the lateral and posterior anorectum and sharpens the anorectal angle and as such contributes to the stool continence mechanism

### **posterior vagina wall**

covers and is attached to the perineal body and anorectum/prerectal fascia/rectum (serosa) and as such is fixed indirectly to the lateral pelvis walls

### **anococcygeal ligament**

from coccyx bone to posterior sphincter ani/anus/anorectum and stabilizes/secures the external sphincter ani and anus in its posterior anatomic position and prevents anterior shifting of external sphincter ani/anus

### **shafik mechanism**

surgically speaking this is difficult to check; as well this could only function if the levator ani muscles are posteriorly uniting around posterior anorectum (true), the anococcygeal ligament around anterior anorectum and/or external sphincter ani and/or perineal body (not true) and bulbospongiosus muscles unite posteriorly from anorectum (not true)

besides this, as long as an anatomically correct reconstruction is performed these structures will be restored as well whatever the arrangement

### **skin with subcutaneous tissue and corrugator ani muscle**

the perianal skin and subcutaneous tissue in combination with corrugator ani muscle around the anus stabilizes the anus as well

### **intact innervation of these components**

autonomic sympathetic and parasympathetic (vagus) nervous system for the ano rectum circular smooth muscle fibers as internal sphincter and longitudinal smooth muscle fibers and for (non)sensibility of anorectum cubic mucosa up to dentate line; from hypogastric and pelvic plexus

Pudendal nerve innervating the external sphincter ani and for sensibility for touch/pain of perianal skin and squamous anorectum mucosa up to dentate line; from s2, s3, s4

Levator ani nerve innervating levator ani muscles; from s3, s4

### **synergistic interaction between stool and urine continence mechanisms**

though the two mechanisms may function independently from each other there is a lot of analogy and synergy; for instance first flatus and then micturition (le vent avant la pluie) and first micturition before defecation, combination of cystocele and rectocele, combination of sphincter ani rupture and genuine intrinsic urine incontinence etc

### **analogy between stool and urine continence mechanism**

analogy of functional anatomy: mucosa, submucous vascular plexus, internal smooth-muscle sphincter, external striated-muscle sphincter and support

analogy of posterior support of urethra by pubocervical fascia and anterior support of sphincter ani/anorectum by perineal body with transversus perinei and bulbospongiosus muscles and by prerectal fascia

analogy of innervation (pudendal nerve + autonomic nervous system)

and analogy of blood supply (internal iliac artery); and for (ano)rectum also inferior mesenteric artery

### **direct against indirect action of levator ani muscles**

tonus and contraction of levator ani muscles have a **direct** action upon the stool continence mechanism since lateral/posterior anorectum walls are being squeezed and fibers of puborectalis support deep part of sphincter ani muscle ani whilst the anorectal angle becomes sharper

tonus and contraction of levator ani muscles have no direct action upon the female urine continence mechanism since there is no direct contact whatsoever between the two; but there is **indirect** action since the pubocervical fascia as attached to the anterior vagina wall is moving anteriorly and cephalad by compression of lateral/posterior vagina walls which improves the support

### **sphincter ani/perineal body complex**

schematic drawings of the sphincter ani/perineal body complex with transversus perinei and bulbospongiosus muscles are presented in fig 75-80

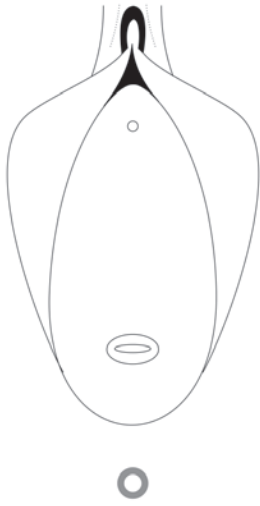


fig 75

sphincter ani

© kees

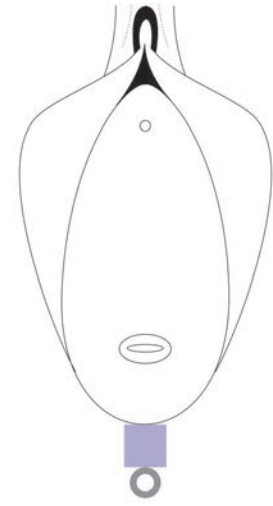


fig 76

perineal body

© kees

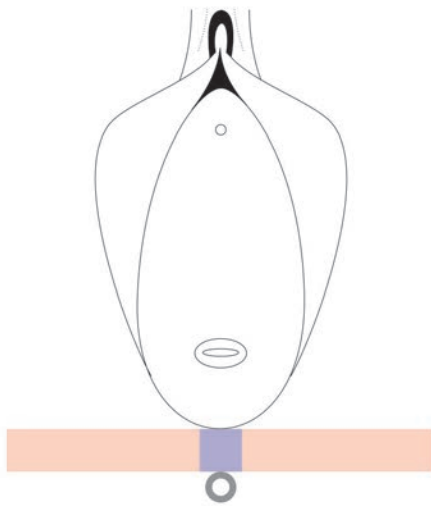


fig 77

transversus perinei muscles

© kees

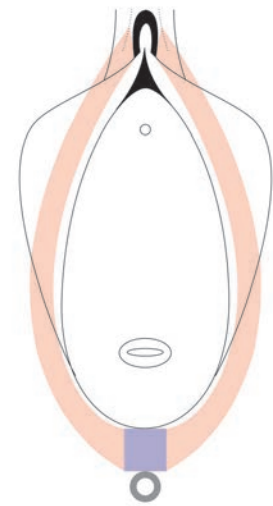


fig 78

bulbospongiosus muscles

© kees

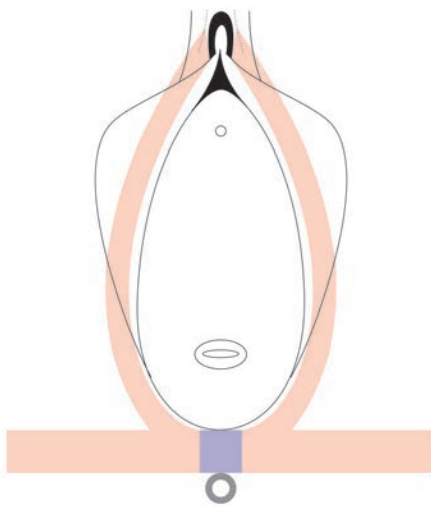


fig 79

sphincter ani perineal body complex

© kees

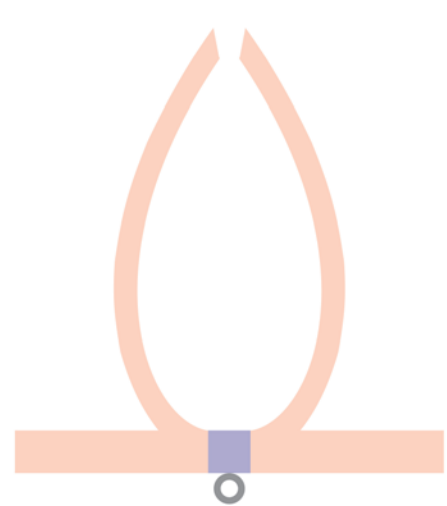


fig 80

sphincter ani perineal body complex

© kees

# levator ani muscles

## value and myth

### introduction

whenever there is a discussion about female continence and female prolapse and intra abdominal pressure the argument is that the levator ani muscles are of paramount importance

however, looking on its anatomic position and structure and what happens once this muscle contracts

can one striated skeletal muscle have so many functions whilst only the pubococcygeus part is well developed

the author is not of this opinion and thinks its action is heavily overrated

so what is true and what is myth

### first its anatomic configuration

only the pubococcygeus muscles seem to be well developed whilst

the iliococcygeus and the (ischio)coccygeus muscles are often only aponeurotic structures

since it is fixed anteriorly to pubis bone and posteriorly to sacrum/coccyx with bilateral fixation to the pelvis wall in a shallow bowl-like shape its center at the anus can only move upwards/cephalad or downwards/caudad depending upon its tonus

with a median longitudinal gap of 25-30 sq cm between the puborectalis ledges it can not be considered a real "pelvis diaphragm" since one third of the total 75-80 sq cm of the pelvis outlet opening is missing

so on its own it cannot counterbalance the intraabdominopelvic hydrostatic pressure; only in combination with the perineum outlet diaphragm

fibers from this muscle crossing the midline underneath the posterior urethra and then uniting with fibers from the other side; and that only at the pelvis outlet level

since the levator ani muscles are encapsulated within a fascia compartment these fibers would have to pierce thru this fascia, already at the level of the atlam, and then pierce thru the intrapelvic urogenital diaphragm to reach the posterior urethra

that would be a strange anatomic configuration

fibers from this muscle crossing the midline up front the anterior external sphincter ani and ano-rectum and then uniting with fibers from the other side; and that as well only at the pelvis outlet level

these fibers would have to pierce thru the fascia before the levator ani muscles unite posteriorly into the levator plate

that also would be a strange anatomic configuration; even more so if combined

and the author never found this kind of fibers during his obstetric trauma surgery

there is direct anatomic contact between the levator ani muscles and the posterior and lateral external sphincter ani, ano-rectum and rectum with radiation of some puborectalis fibers into the deep portion of the external sphincter ani

there is no anatomic contact between the levator ani muscles and (posterior) urethra, bladder, cervix/uterus, intraperitoneal contents and the anterior rectum wall

actually the urogenital organs, intraperitoneal contents and their supporting intrapelvic urogenital diaphragm are cephalad to the anatomic position of the levator ani muscles

## what happens when the levator ani muscles contract

first it is fixed to the pubis body and the coccyx bone; so as a whole it can only increase its tonus whereby

the deepest point of the bowl-like structure at the anus will move upwards/cephalad

second, the puborectalis will pull the ano-rectum forwards towards the symphysis but this pull is counteracted by increase in tonus of the levator plate with a sharpening of the rectum/ano-rectum angle

third, the gap in between the two puborectalis edges will become a bit more triangular posteriorly at the anus since the two are fixed to the pubis bones with a minimum distance in between of 3.5-4 cm

more is not possible anatomically and functionally speaking

fourth they will squeeze directly the (bi)lateral and posterior ano-rectum walls and as such will contribute directly and positively to the stool continence mechanism

fifth they will squeeze the (bi)lateral vagina wall directly and the posterior vagina wall indirectly via the rectum which indirectly will push the anterior vagina wall forward and cephalad with indirectly a positive effect upon the urine continence mechanism

since there is nowhere direct anatomic contact between the levator ani muscles and the urinary tract, and especially the bladder and urethra, there cannot be a direct action upon the urine continence mechanism

whilst also the anatomic support of the urine continence mechanism by the intrapelvic urogenital diaphragm is cephalad to the atlam and levator ani muscles



it is only in combination with the perineum outlet diaphragm which is connected to and supported by the pelvis diaphragm in the region of the anus as pelvis floor that there may be a positive action upon the urine continence mechanism and stool continence mechanism since

all the outlet end parts of the urinary tract, the genital tract and the digestive tract together with their continence mechanisms are firmly anchored into the perineum outlet diaphragm and contraction of its muscles and increase in its tonus will have a direct positive effect upon the urine and stool continence mechanism whilst closing the introitus

stabilization and securing the posterior bladder, the posterior urethra, the cervix/uterus and intraperitoneal organs and anterior rectum in their anatomic position without herniating into the vagina cannot be influenced neither by the pelvis diaphragm nor by the perineum outlet diaphragm

these functions are taken care of by the fascia structures of the corpus intrapelvinum in between these high(er)-pressure organs and the zero-pressure vagina

## conclusion

### **support of continence mechanisms**

though the levator ani muscles are directly supporting the anatomic stool continence mechanism they are only indirectly supporting the urine continence mechanism

the perineum outlet diaphragm is directly supporting the stool continence mechanism and the urine continence mechanism

combination of the pelvis diaphragm and perineum outlet diaphragm as pelvis floor as one functional unit is supporting and the urine continence mechanism and the stool continence mechanism directly and indirectly

pelvis floor muscle exercises have a direct and indirect positive effect upon the urine continence mechanism and the stool continence mechanism

### **intraabdominal pressure**

to counteract abdominal pressure the “pelvis diaphragm” is insufficient due to the fact that one third of the surface required to close the outlet is missing

the perineum outlet is far better equipped to do that since the end organs with their walls are firmly anchored into it sealing off the openings

combined as pelvis floor it will function; the perineum more anteriorly and the pelvis diaphragm more posteriorly

however the first line of counteracting abdominal pressure is the intrapelvic urogenital diaphragm whilst

the pelvis floor is the second and last line

## **stabilization of anatomic position**

since there is nowhere direct contact between the levator ani muscles and the prolapse prone organ (walls) like posterior urethra, posterior bladder (base), cervix/uterus, intra peritoneal contents and anterior rectum

the levator ani muscles cannot stabilize these organs (wall) in their anatomic position

since there is nowhere direct contact between the perineum outlet diaphragm and the prolapse-prone organ (walls) like posterior urethra, posterior bladder (base), cervix/uterus, intraperitoneal contents and anterior rectum

the perineum outlet diaphragm cannot stabilize these organs (wall) in their position

even combined as pelvis floor they cannot stabilize these organs (wall)

since

herniation of the urogenital and digestive organs is thru defects in the fascia structures of the corpus intrapelvinum in between these high(er)-pressure organs and the zero-pressure vagina

once herniated into the vagina they may prolapse unopposed to the outside thru the openings in the pelvis diaphragm and the perineum outlet diaphragm dragging the vagina wall with them as intussusception

even the pelvis diaphragm and the perineum outlet diaphragm combined as pelvis floor can neither prevent not stop this process right from the beginning to the end

therefore another concept of **intrapelvic urogenital diaphragm** is presented

# pelvis floor muscle exercises

## mechanism of action

### introduction

empirically, pelvis floor (levator ani + perineum) muscle exercises have a positive effect upon urine intrinsic stress incontinence

however, though it is recommended everywhere by everybody the author could not find an explicit explanation for this action

### functional anatomy

the pubococcygeus muscles envelop the vagina three-quarterly bilateroposteriorly as a sling being in direct contact with the bilateral vagina walls and in indirect contact (via anorectum) with the posterior vagina wall

the open anterior/cephalad one quarter gap is filled up by the symphysis and anterior vagina wall with adherent pubocervical fascia with adherent posterior bladder base, posterior uv-junction and posterior urethra whilst

all the continence mechanisms are firmly anchored into the perineum outlet diaphragm

### mechanism of action

when the pubococcygeus muscles contract they squeeze the posterior and bilateral vagina walls with the effect that the anterior vagina wall (not squeezed) moves anteriorly and cephalad together with the adherent pubocervical fascia with adherent posterior bladder neck, posterior uv-junction and posterior urethra wall

this will reinforce the intrinsic urine continence mechanism since the posterior urethra wall will “rotate forward” towards the anterior urethra wall and symphysis resulting in a better arrangement/architecture of the anatomic urine continence mechanism; so a positive effect but **indirectly**

the simultaneous contraction of the muscles with increase in the tonus of the perineum outlet diaphragm will **directly** have a positive effect on all the continence mechanisms since these are firmly anchored into it

at the same time there will be an increase in the extrinsic rhabdosphincter forces by voluntary and/or reflex contractions

however, there is no guarantee of success since it will only be successful if

now by this action the total amount of forces closing the urethra will be higher than the intravesical excretion pressure

## optimal way of using pelvis floor muscles

one first contracts the pelvis floor muscles before standing up or before coughing so that the configuration of the anatomic urine mechanism is optimal just before there is an increase in (intraabdominal and so in) intravesical pressure

if one does this regularly first their action will become stronger and second our able brain will create special pathways for it and it may become a reflex

## discussion

it is good to realize that the pelvis floor functions as one dynamic unit with an indirect action by the levator ani muscles and a direct action by the perineum outlet diaphragm upon the urine continence mechanism

whereby the action of the levator ani muscles is reinforced by the simultaneous action of the perineum outlet diaphragm and the other way round since

they are firmly connected to each other via the perineal body and the external sphincter ani complex

with perineal body as centrum tendineum perinei since all the relevant structures are firmly anchored into it

# obstetric trauma

## introduction

obstetrics constitutes always a major challenge to all pelvis organs with their different structures

here the author would like to give an outline and then in future books give specified details for pressure necrosis trauma due to prolonged obstructed labor

## analysis

there are several mechanisms by which the intrapelvic organs may be affected which will influence the functional pelvis anatomy in one way or the other

first by hormonal flooding

second by continuously increasing hydrostatic pressure due to pregnant uterus

third by dilatation of the cervix with opening up of the intrapelvic urogenital diaphragm

fourth by direct or indirect cutting thru of the head thru the cervix, thru the gap between the puborectalis ledges and thru the opening within the perineum outlet diaphragm

fifth by shearing forces during actual childbirth when the head passes thru the cervix, thru the vagina, thru the gap between the levator ani ledges and thru the opening in the perineum outlet diaphragm

sixth by compression of the soft tissues between the hard fetal skull and the bony maternal pelvis

### hormonal flooding

all the tissues will first “hypertrophy” to withstand the increased hydrostatic pressure and later on will soften as preparation for childbirth and will involute during the puerperium

### hydrostatic pressure

since the fetus and the uterus will grow slowly there is a continuously increasing hydrostatic pressure which may traumatize the intrapelvic urogenital diaphragm despite “hypertrophy”; in the involution phase defects may be resolved spontaneously or small defects remain

with subsequent pregnancies/deliveries these remaining defects may become larger up to a point where support of the urinary continence mechanism becomes defective and/or the securing/stabilization of the organs become defective

### dilatation of cervix with opening of intrapelvic urogenital diaphragm

during the first stage of labor the cervix will efface and with it the urogenital diaphragm will open up with possible trauma to the anchoring of the cervix into this diaphragm when the head passes thru this opening it may further stretch/traumatize the tissues either bluntly or sharply

### cut-thru trauma

when the passing of the head thru the birth canal goes too quick or when the birth canal is not fully dilated and the tissues have not time to stretch the head may cut thru the tissues either bluntly or sharply as

blunt cut-thru

in combination with stretching the bilateral ledges of the puborectalis muscles may be traumatized

in combination with stretching the perineum outlet diaphragm may be traumatized resulting in a wide introitus

sharp cut-thru

when the cervix is not fully dilated the head may further traumatize the cervix and its anchoring into the intrapelvic urogenital diaphragm

when the perineum outlet is too stiff the head may cut thru the perineum, sphincter ani and rectum resulting in the complex sphincter ani rupture

### shifting/shearing

when the head of the infant passes thru the birth canal always shearing will take place in minor or major form

between the head and the vagina wall

between the vagina wall and the intrapelvic urogenital diaphragm,

between the urogenital diaphragm and its attachment to the pubis bone and obturator internus muscle fascia and

between the arcus tendineus of the levator ani muscles and the obturator internus muscle fascia

### compression trauma

when the head passes thru the vagina there will be compression of the soft tissues between the hard fetal skull and the maternal bony pelvis

normally this is not a problem during physiologic childbirth but when obstructed labor develops which is not relieved in time pressure necrosis will develop in an endless variety; from minimal to extensive anatomic tissue loss

## discussion

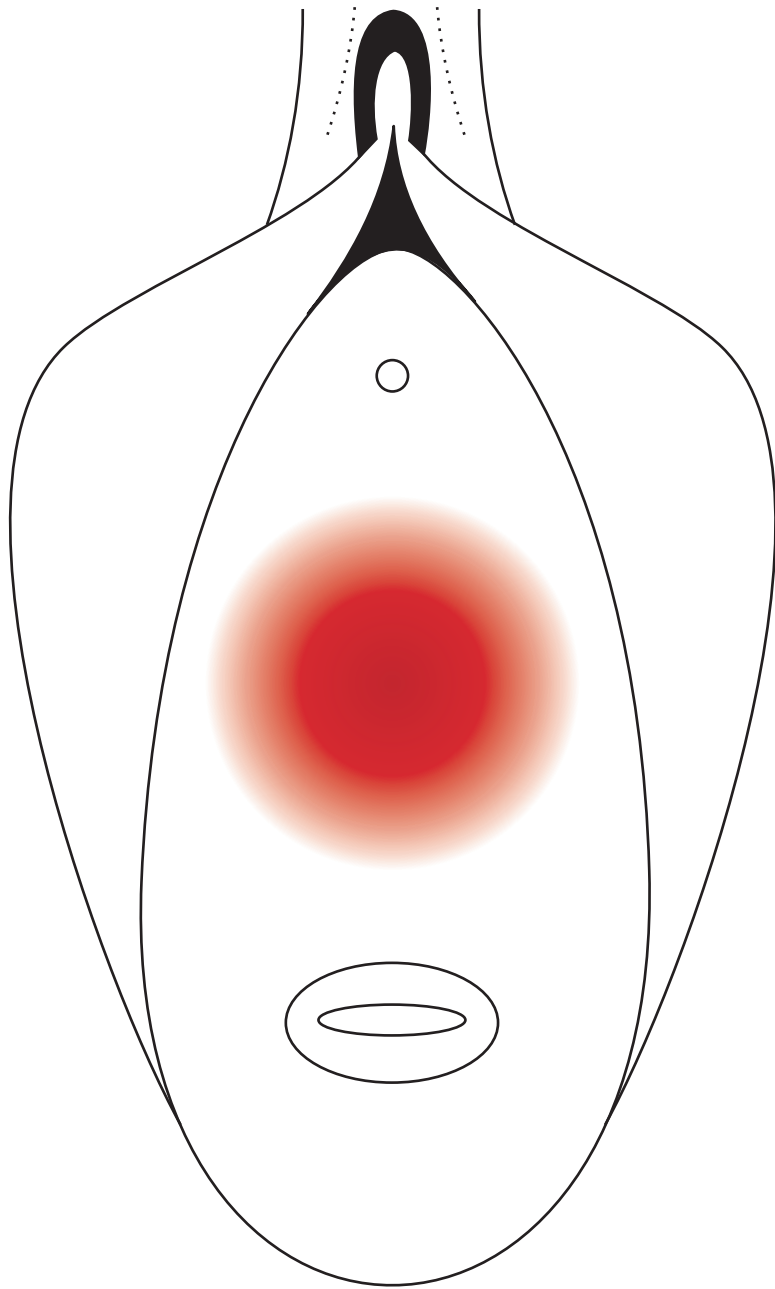
there are always tissue changes and tissue trauma during pregnancy and childbirth even in physiologic pregnancy/labor

normally these changes/trauma will be resolved during the involution period of the puerperium though small defects may remain

repeat pregnancies/deliveries will repeatedly add to these small defects and may result in real pathologic defects

however, when labor becomes obstructed and this is not relieved in time pressure necrosis will develop resulting in an endless variety of anatomic tissue loss with devastating consequences for the woman affected

as will be explained in the series **obstetric trauma surgery; art and science**



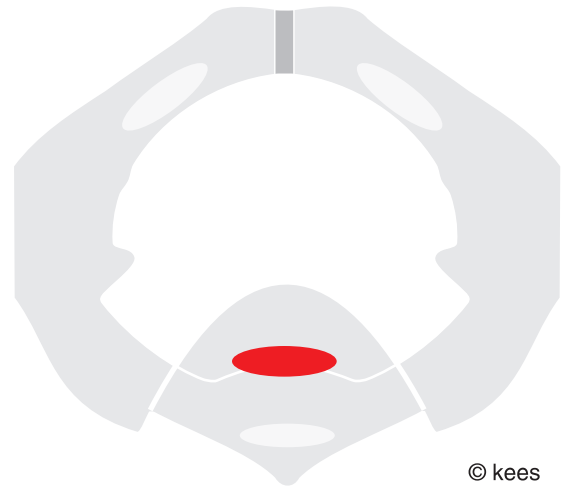
© kees

pressure gradient



© kees

fig 81 anterior trauma



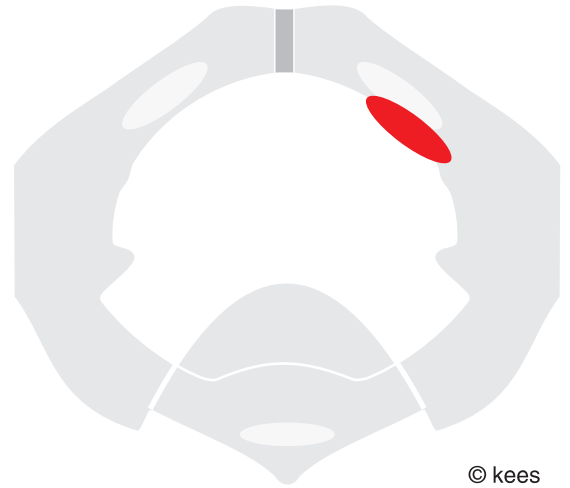
© kees

fig 82 posterior trauma



© kees

fig 83 anterolateral trauma left



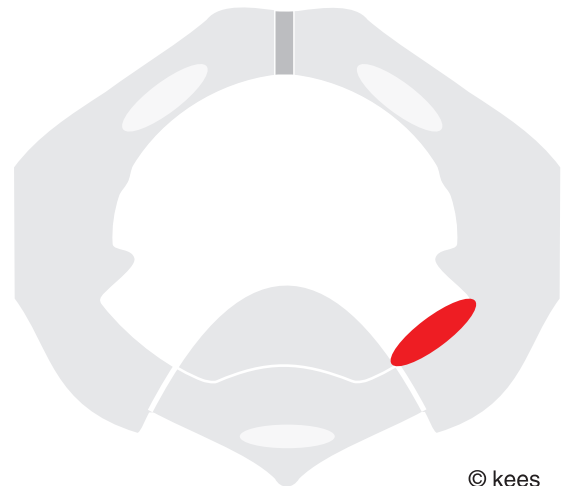
© kees

fig 84 anterolateral trauma right



© kees

fig 85 posterolateral trauma left



© kees

fig 86 posterolateral trauma right





© kees

fig 87 anterior trauma



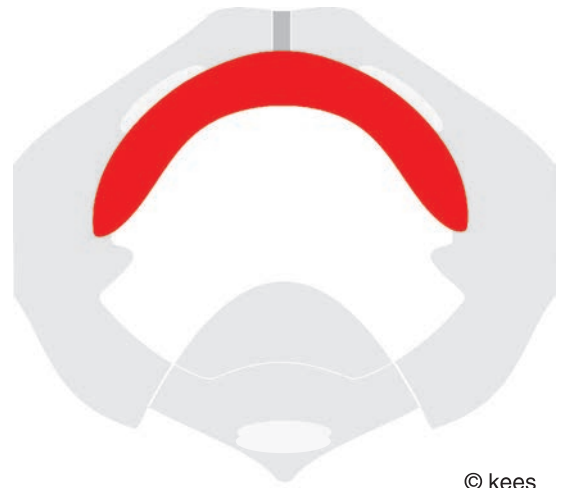
© kees

fig 88 anterolateral trauma right



© kees

fig 89 anterolateral trauma left



© kees

fig 90 anterobilateral trauma



© kees

fig 91 posterior trauma



© kees

fig 92 posterolateral trauma right



© kees

fig 93 posterolateral trauma left



© kees

fig 94 posterobilateral trauma



© kees

fig 95 lateral trauma left



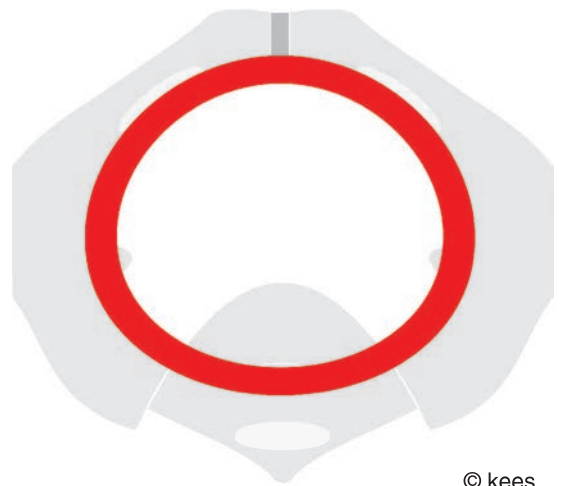
© kees

fig 96 lateral trauma right



© kees

fig 97 semicircumferential trauma



© kees

fig 98 total circumferential trauma

# mechanism of urine stress incontinence

genuine and post fistula repair

## introduction

if one wants to perform reconstructive surgery one must know the anatomy and the mechanism of action of continence and of incontinence

here a short outline is given about the mechanism of urine stress incontinence either in genuine incontinence or post fistula repair stress incontinence

as based upon the systematic examination/assessment/documentation/analysis of various defects and tissue loss of the continence mechanism from one cell to total loss as a “natural experiment” within the complex obstetric trauma

stress incontinence is always an expression of defective intrinsic forces, in genuine incontinence without tissue loss and in post fistula repair with anatomic tissue loss

## mechanism of urine stress incontinence

the anterior urethra wall is adherent to the posterior symphysis by loose connective tissue and a thin fluid film which allows the anterior urethra wall to shift against the symphysis friction free, though little; however it cannot rotate backwards away from the symphysis

the posterior urethra wall is firmly adherent to the pubocervical fascia with pubourethral ligaments as part of the intrapelvic urogenital diaphragm

if defects develop within this diaphragm the posterior urethra wall will rotate backwards away from the symphysis causing partial (or total) funneling of the proximal (or total) urethra since the anterior urethra wall stays sticking against the symphysis; this process is called vesicalization since functionally the funneled part of the urethra becomes part of the bladder (vesica)

besides backward rotation there is also backward shifting of the posterior urethra wall against the anterior urethra wall into the direction of the sacrum; since the anterior external opening is fixed and immobile

these two mechanisms of pathophysiologic action result into a wider (proximal) urethra lumen and a more oval elliptical arrangement of the smooth muscle fibers and

interfere with the intrinsic forces keeping the urethra closed since more force is needed to close the urethra; less resistance according to poiseuille law

once the intrinsic forces can no longer keep the urethra closed sufficiently this will lead to genuine intrinsic stress incontinence in various degrees

in total intrinsic stress incontinence there is continuous leaking of urine on lying/sitting/standing/walking due to total loss of the intrinsic forces

intraoperatively under spinal anesthesia in these patients in the exaggerated lithotomy position the level of urine within the urethra is noticed in concord with respiration, rising on expiration and lowering on inspiration

the external opening is anchored into the perineum outlet diaphragm and anteriorly firmly connected to the anterior symphysis whilst

the anterior urethra, anterior uv-junction and anterior bladder neck are connected/firmly adhesive to the posterior/inferior symphysis by loose connective tissue and thin fluid film and

the anterior bladder is connected/firmly adhesive to the posterior symphysis and the anterior abdominal wall by loose connective tissue and thin fluid film

in the upright position the anterior bladder neck, anterior uv-junction and anterior urethra wall are resting upon and pressed against the posterior symphysis

as such the anterior urethra, anterior uv-junction and anterior bladder can shift friction free against the posterior symphysis; but they cannot rotate backwards away from it due to the strong negative pressure exerted within the thin fluid film on pull/traction

there are two forces at work which exert traction upon the mobile posterior uv-junction and posterior urethra wall whereby the architecture of the urethra wall will be distorted

first the uv-junction and proximal urethra are pulled and pushed open and the urethra becomes functionally part of the bladder (vesicalization)

as long as the remaining intrinsic continence mechanism is strong enough the woman is still continent but once the intrinsic continence mechanism cannot cope any more with increased intravesical pressure there is urine loss

though this is called genuine stress incontinence actually it is intrinsic incontinence

later there will be opening up of the whole urethra (total vesicalization)

the posterior urethra wall is pulled away from the anterior urethra wall opposite to the direction of coaptation

besides this the posterior urethra wall is pulled towards the cervix/sacrum as well with posterior deformation of the external urethra opening so that the smooth muscle fibers become more oblique and continent closure is no longer possible and the woman loses urine more or less continuously whilst lying/sitting/standing/walking, with or without spontaneous miction

the first force is downward due to herniation of the posterior bladder/posterior bladder neck/posterior uv-junction/posterior proximal urethra thru the median defect in the pubocervical fascia as seen in cystocele

or as due to a loose pubocervical fascia since its connection to the arcus tendineus fasciae has been lost either directly as in circumferential fistulas or indirectly by a transverse defect in the pubocervical fascia

the second force is posterior into the direction of the cervix/sacrum due to pull by the herniated and/or sagging down posterior bladder wall

this second force can be the main mechanism of incontinence as noticed when a longitudinal median scar from the external urethra opening to cervix (due to mutilating incision) keeps on contracting throughout life since it is perpendicular to the ruga folds

it can also be seen after a caesarean section whereby the cervix is fixed intraabdominally and moves cephalad on cough with posterior traction onto the pubocervical fascia/anterior vagina wall

it is seen frequently in ureter fistulas type III due to its posterior traction effect onto the pubocervical fascia/anterior vagina wall; once there is vesicalization a downward force will come in as well

the third possibility is a trauma to the anchoring of the distal urethra and its external opening into the perineum outlet diaphragm; with or without an avulsion of the distal urethra and its external opening

## defects within the intrapelvic urogenital diaphragm

there are defects without tissue loss as in genuine incontinence and defects with anatomic tissue loss as in post fistula repair incontinence

in **genuine incontinence** without tissue loss

normally one will find a median longitudinal defect whereby the posterior urethra wall is no longer supported

however, transverse defects with indirect loose connection to the pubis bone and arcus tendineus fasciae = atf may also be found

and direct loose connection

either isolated or combined; as well in combination with urogenital prolapse

in **post fistula repair incontinence** with anatomic tissue loss

the variety is great as is the variety in anatomic tissue loss

median longitudinal defects with loss of support of the posterior urethra wall

transverse defects with indirect loose connection to pubis bones/pelvis wall

quatercircular defects with (in)direct loose connection to pubis bones/pelvis wall and loss of atf

semicircular defects with (in)direct loose connection to pubis bones/pelvis wall and loss of atf and atlam and cephalad part of levator ani muscles etc

(sub)total loss with major pelvis soft tissue loss

the more extensive the anatomic tissue loss the more chance of incontinence

all these defects may be combined with anchoring defects into the perineum outlet diaphragm

## defects within the anchoring into the perineum outlet diaphragm

since the anterior external urethra is firmly fixed and as such the anterior urethra wall also secured defects will lead to shifting of the posterior urethra wall and external opening towards the sacrum with wide opening of the external urethra opening and hourglass or sandglass deformity of the urethra

this anchoring defect is normally combined with a median longitudinal defect within the intrapelvic urogenital diaphragm

this is a rather frequent finding especially in fresh postpartum genuine incontinence

however, total avulsion of the distal urethra and external opening out of its anchoring may occur though it is rare

the author encountered this only 4 times, once due to direct trauma, once due to infection and twice due to obstructed labor

## discussion and practical consequences

the obstetric fistula surgeon is in a unique position to study the female urine continence mechanism by direct observation of an endless variety of the natural experiment of the complex obstetric trauma in all its forms

the term intrinsic stress incontinence is preferred above stress incontinence since it is the intrinsic continence mechanism which is defective and has to be corrected

the art of reconstructive surgery is to first assess the trauma and then to reconstruct only the functional anatomy so that physiology will be restored by physiologic stress

since any patient with urine incontinence is unique, once the general principles have been outlined the operation technique has to be customized to correct the specific individual lesions; a standard trick may work but it is insight that counts

for intrinsic stress incontinence a physiologic reconstructive operation technique has been developed which only corrects the defects in the pubocervical fascia with tightening if necessary

these principles may be of value to the industrialized world as well since most operation techniques are tricks and nonphysiologic

for all fistulas, type **I**, type **IIAa**, type **IIAb**, type **IIBa** and type **IIBb**, operation principles have been developed to correct the respective defects in the pubocervical fascia and its fixation already during the repair to prevent postrepair incontinence

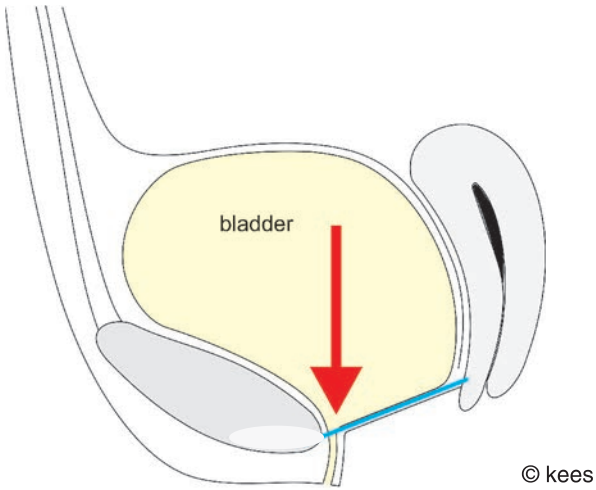


fig 99 downward force

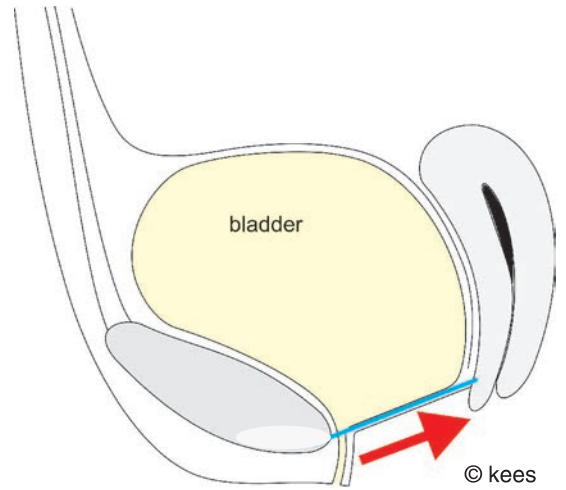


fig 100 force towards cervix/sacrum

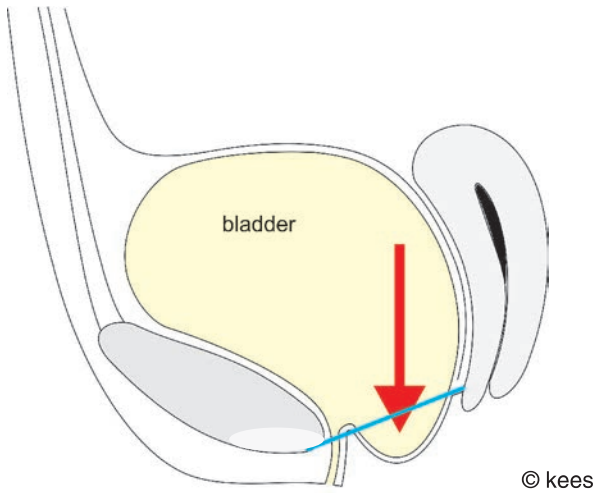


fig 101 downward force  
cystocele  
median defect pc fascia

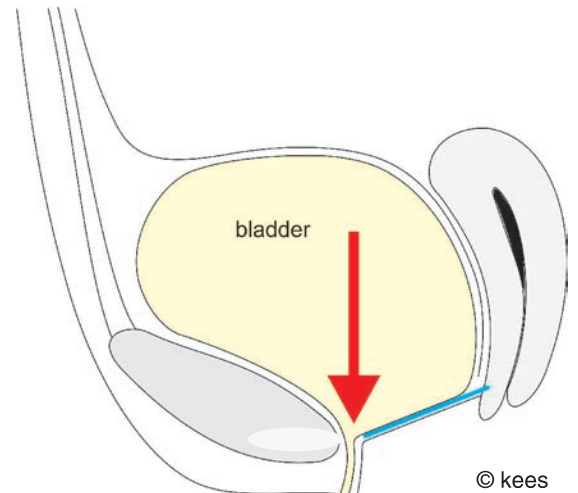


fig 102 downward force  
no connection pc fascia to atf

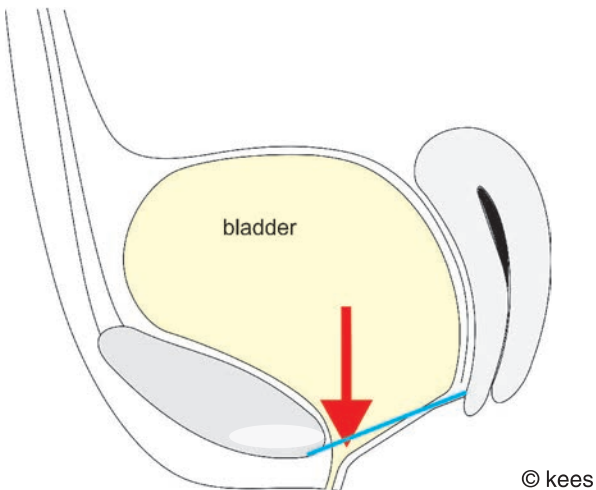


fig 103 vesicalization proximal urethra

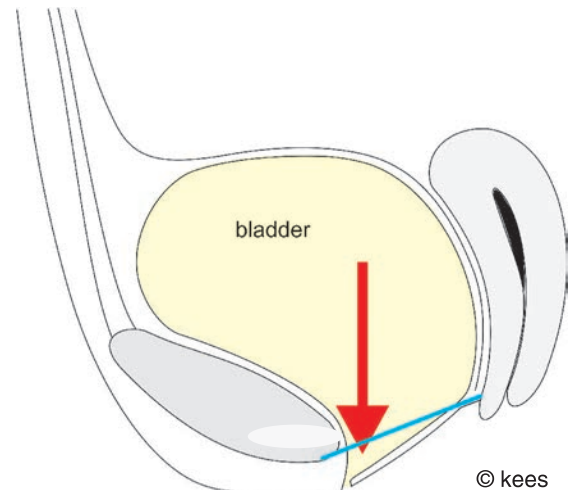


fig 104 total vesicalization

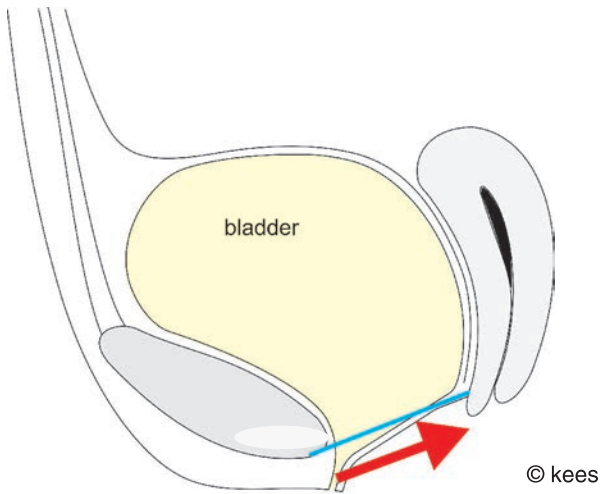


fig 105 vesicalization proximal urethra

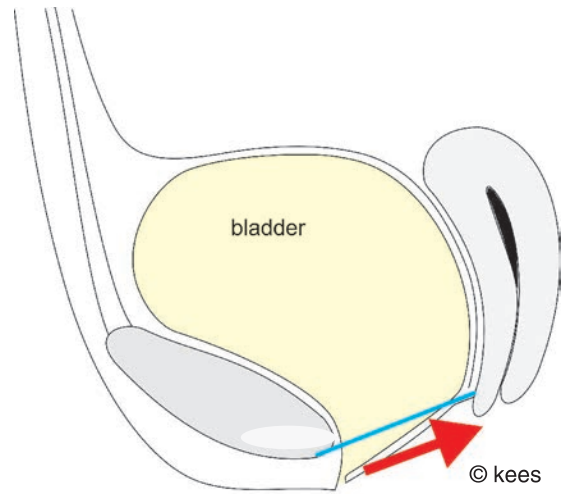


fig 106 total vesicalization

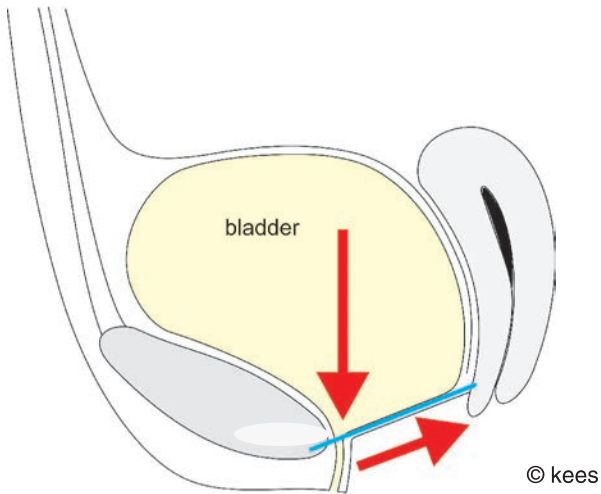


fig 107 downward/backward force combined

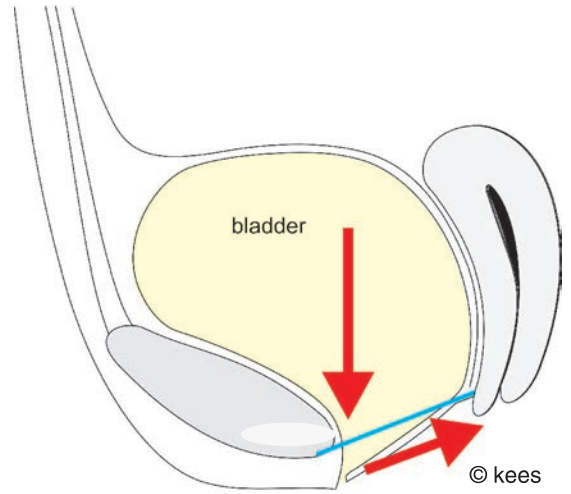


fig 108 total vesicalization

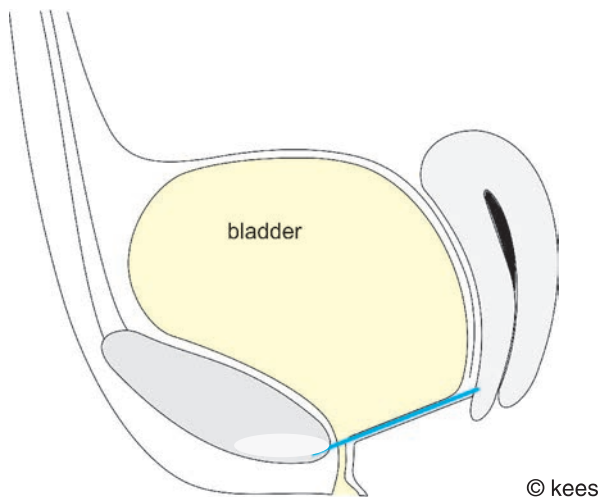


fig 109 anchoring trauma perineum outlet diaphragm

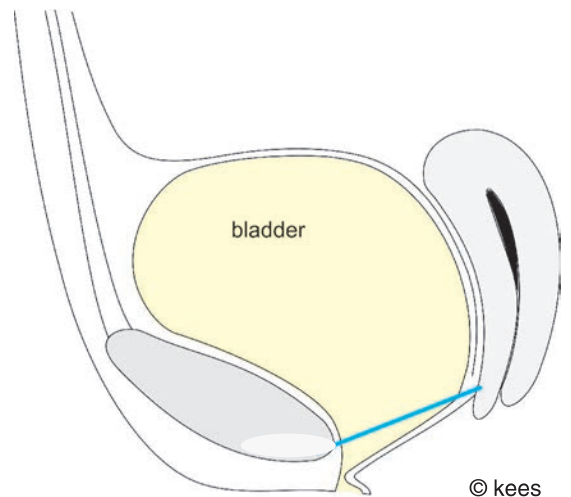
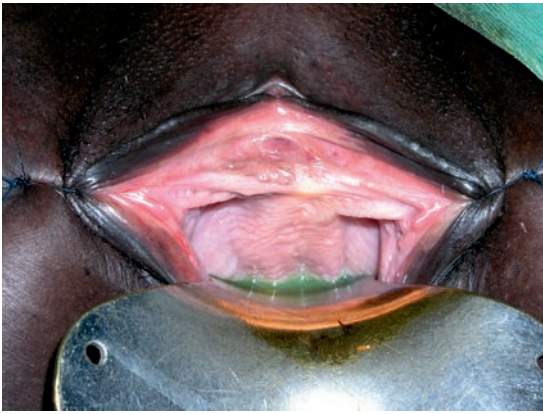

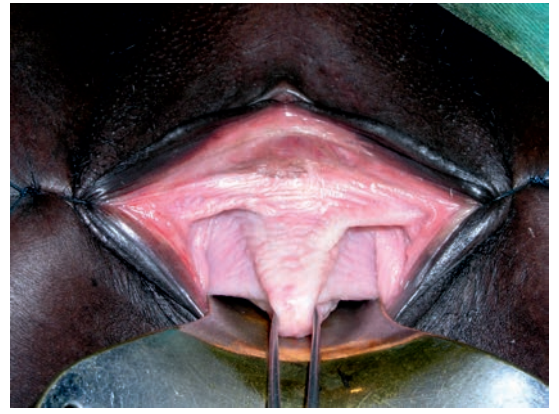fig 110 hourglass urethra





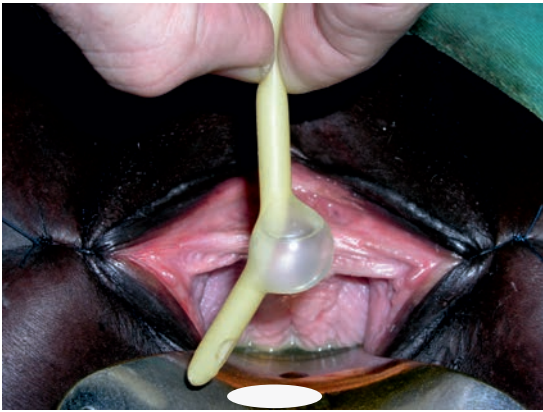© kees

fig 111 intrinsic incontinence



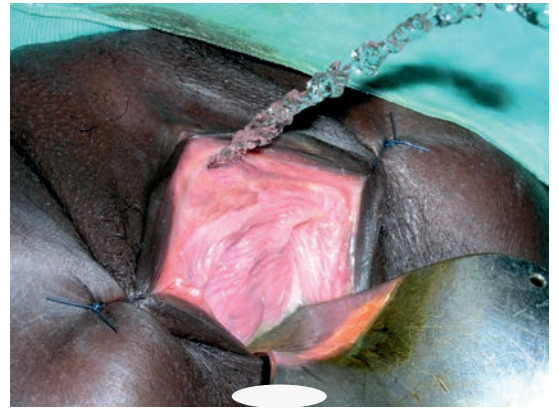
© kees

fig 112 median fascia defect



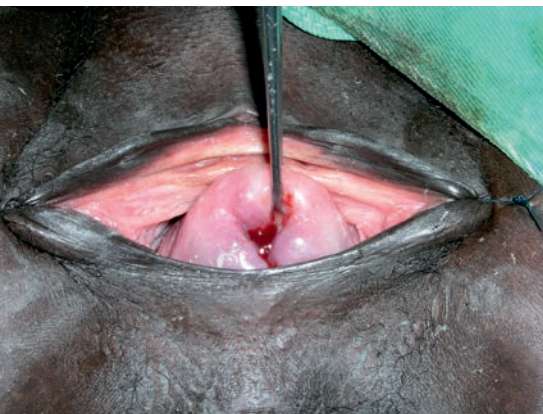© kees

fig 113 urethra length



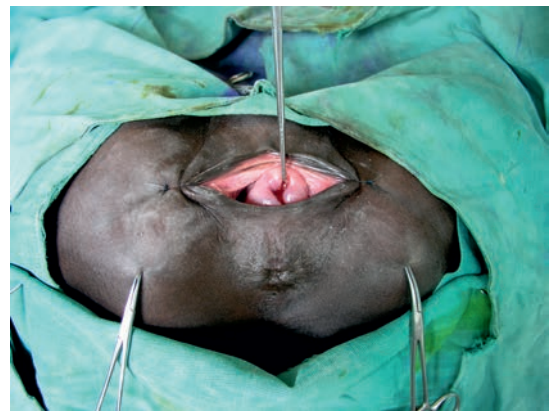© kees

fig 114 objective incontinence



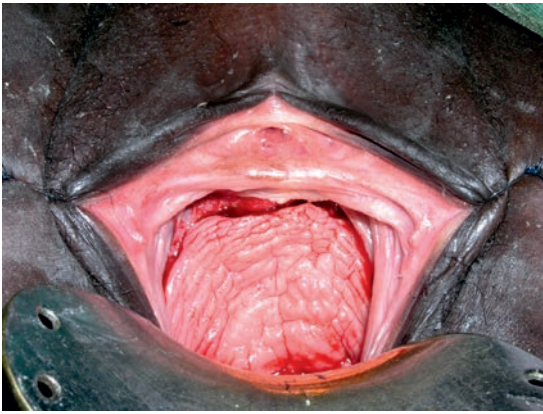© kees

fig 115 2° cervix prolapse



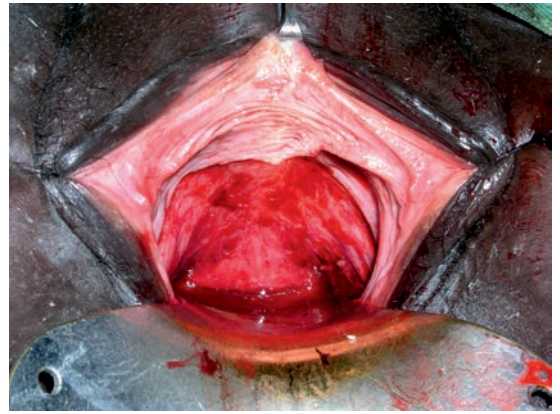
© kees

fig 116 wide pubic arch



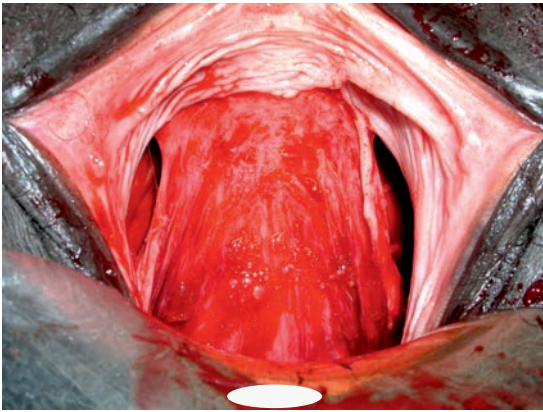
© kees

fig 117      physiologic incision



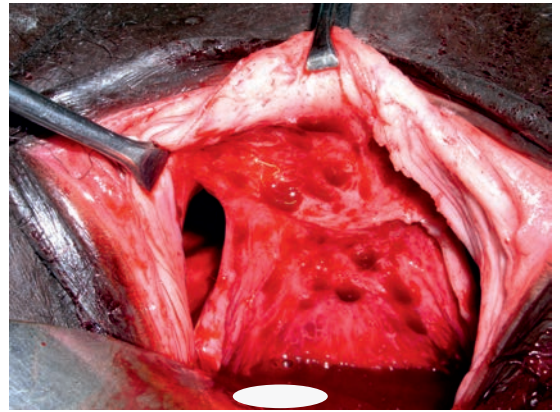
© kees

fig 118      dissection



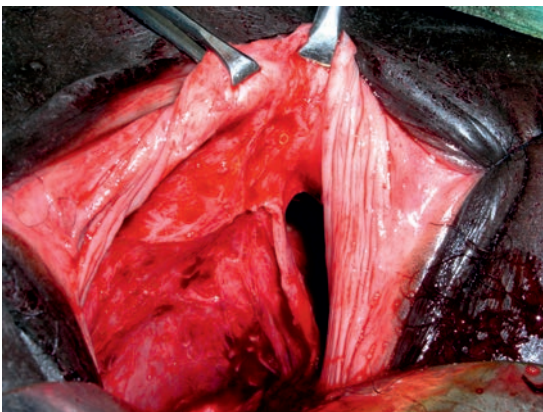
© kees

fig 119      pubocervical fascia  
longitudinal fibers



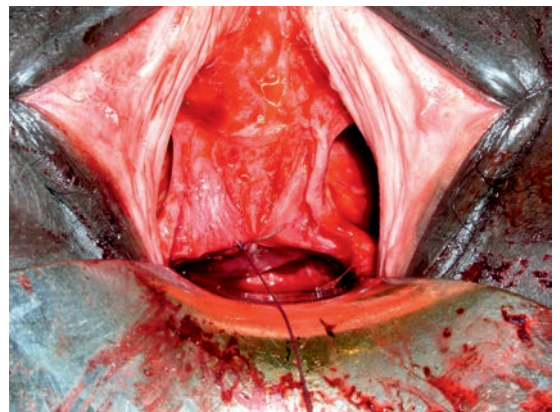
© kees

fig 120      paravesical space right  
transverse fibers  
underneath urethra



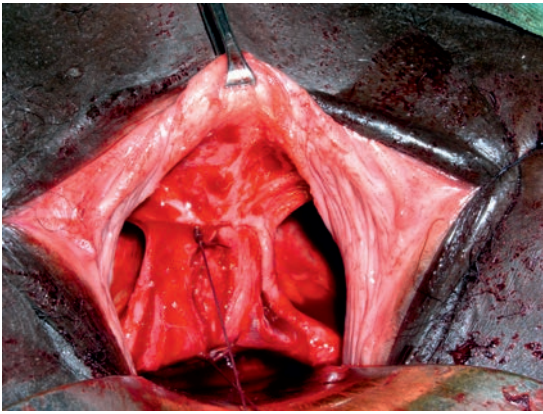
© kees

fig 121      paravesical space left



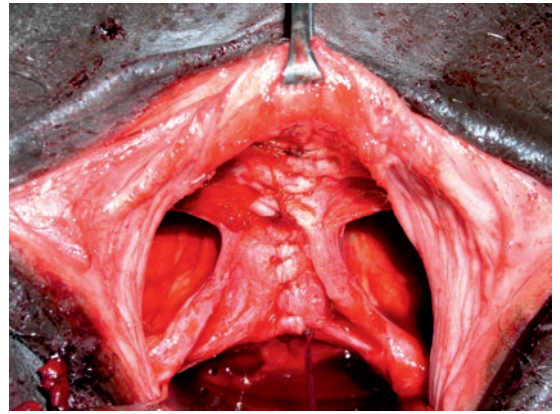
© kees

fig 122      median fascia defect



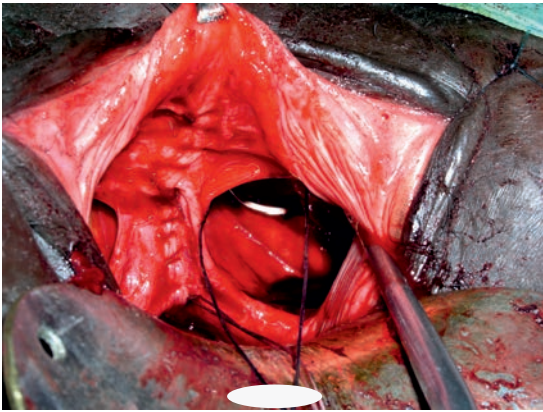
© kees

fig 123 longitudinal fascia repair



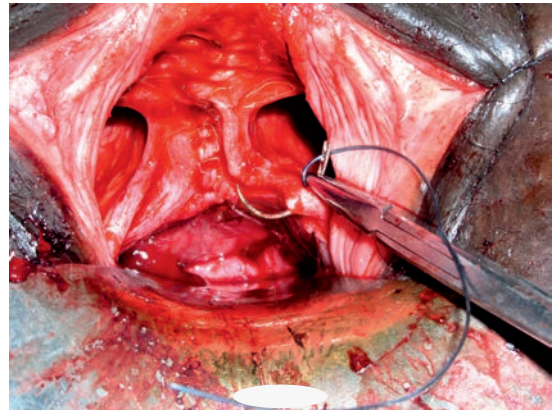
© kees

fig 124 repair completed



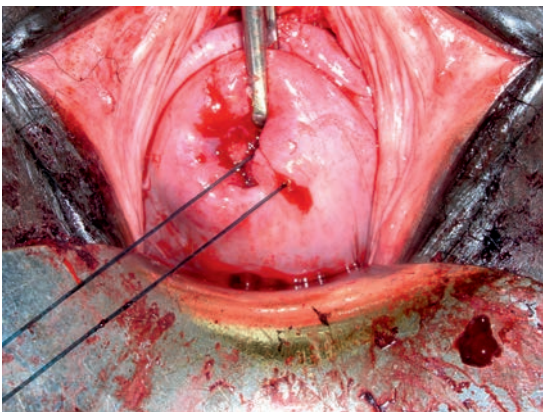
© kees

fig 125 fascia refixation onto atf left



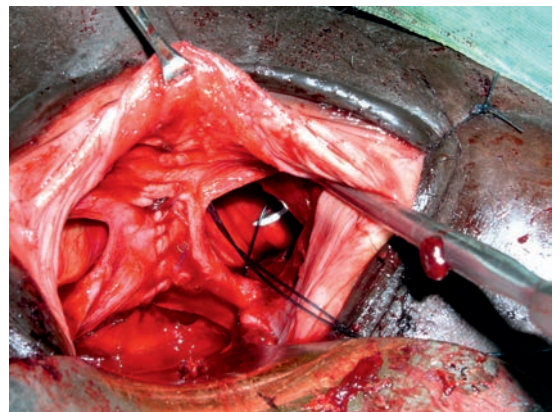
© kees

fig 126 fascia refixation onto atf left picking up fascia



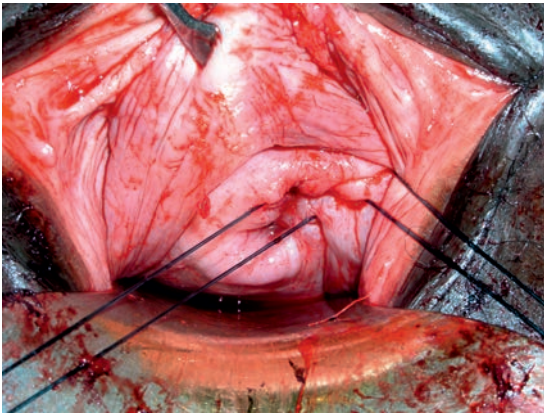
© kees

fig 127 cervix fixation



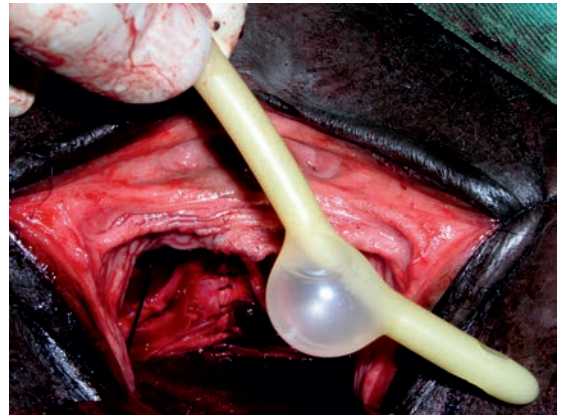
© kees

fig 128 fascia refixation onto atf left second suture



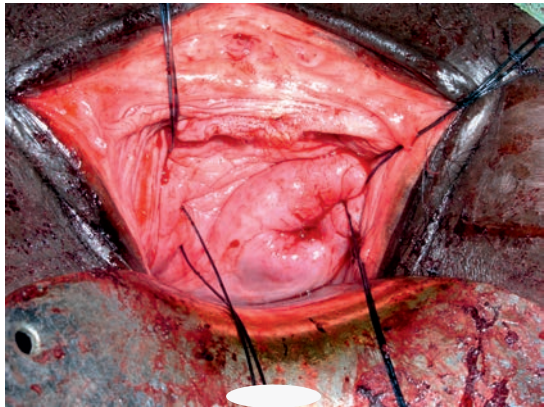
© kees

fig 129 cervix fixation



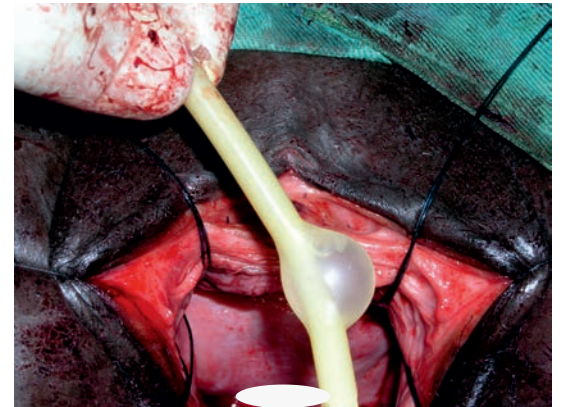
© kees

fig 130 urethra length



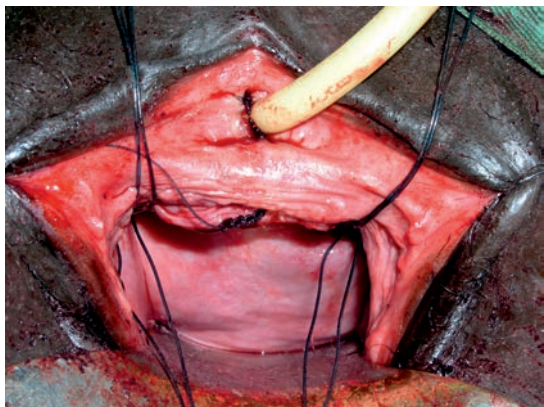
© kees

fig 131 all sutures in place



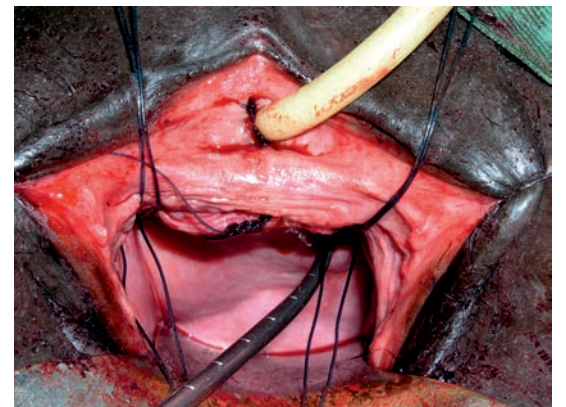
© kees

fig 132 urethra length



© kees

fig 133 fixation completed



© kees

fig 134 repair completed  
cervix well fixed

# urogenital and digestive prolapse

## mechanism of action

as based on intraoperative findings

### introduction

since the vagina is a low- or zero-pressure organ the vagina cannot herniate into its adjacent organs with high(er) pressure whilst these high-pressure organs can easily herniate into the vagina once defects develop within the separating and supporting corpus intrapelvinum structures in between these organs

once the organs herniate into the vagina they can further prolapse unopposed to the outside whilst dragging the vagina (wall) with it

the distal end organs of the urinary tract, genital tract and digestive tract together with their respective anatomic continence mechanism are anchored into the perineum outlet diaphragm

so these end organs can only prolapse to the outside by kind of intussusception, for instance like total cervix/uterus prolapse thru the introitus

the pelvis floor with its large hernia-prone openings can neither prevent nor stop this process

the wider the pelvis the wider the span in between its side walls and the more chance of developing prolapse

considering a pubic arch (indication of pelvis width) of 85° as normal; as corresponding with a normal width pelvis

a pubic arch of 90° seems to be the critical point

in almost all the patients the author operated for some kind of prolapse he found a pubic arch of  $\geq 90^\circ$  since he started measuring this arch

this was also found in patients with genuine intrinsic stress incontinence and in patients with obstetric anterior sphincter ani rupture

### prolapse

#### urethrocele

herniation of the posterior urethra into the vagina thru a median defect within the urethrovaginal fascia as most anterior part of the intrapelvic urogenital diaphragm

#### cystocele

herniation of the posterior bladder into the vagina thru a median defect within the pubo-cervical fascia as anterior part of the intrapelvic diaphragm

**cervix/uterus prolapse**

herniation of the cervix/uterus into the vagina thru a central defect in the intrapelvic urogenital diaphragm

**enterocele**

herniation of intraperitoneal contents (ileum) thru a defect within the rectovaginal fascia in between the sacrouterine ligaments as most posterior part of the intrapelvic urogenital diaphragm

**rectocele**

herniation of the anterior rectum thru a median defect within the rectovaginal fascia and perineal body

these prolapses may occur isolated or combined in any combination

**rectum prolapse thru anus**

intussusception of the rectum thru a defective anatomic stool continence mechanism

**urethra caruncle**

intussusception of urethra mucosa thru external urethra opening

**mechanism of action**

the intact intrapelvic urogenital diaphragm with its specialized structures stabilizes and secures the bladder and urethra and the cervix in their variable anatomic position and prevents the intraperitoneal contents from herniating into the vagina

except for the distal urethrovaginal fascia where the fibers seem to be transverse the fibers of the pubocervical fascia seem to be longitudinal

their weakest point is in the midline (where the span is the broadest and the pressure the highest) where due to hydrostatic pressure the longitudinal fibers may start to divide/split whereby these fibers retract (bi)laterally and median defect(s) will develop

then depending upon the position of the defect the posterior urethra, bladder base, cervix and/or intraperitoneal contents (ileum) herniate thru this defect into the zero-pressure vagina as urethrocele, cystocele, cervix prolapse or enterocele

if not corrected the herniated organs may prolapse unopposed to the outside thru the vagina thru openings within the pelvis floor dragging the anterior vagina wall with them by intussusception

the mechanism of rectocele is a bit different since hydrostatic pressure is not involved but it is by obstetric or other trauma causing a median defect within the rectovaginal fascia and perineal body

then the high-pressure (anterior) rectum (wall) will herniate thru this defect into the zero-pressure vagina and may further prolapse unopposed to the outside thru the opening into the pelvis floor dragging the posterior vagina wall with it by intussusception

## discussion

it is crucial to understand that the mechanism of action is by defects within the fascia structures of the corpus intrapelvinum between the high(er)-pressure adjacent organs and the zero-pressure vagina

and as such the organs will first herniate into the vagina; only at a later stage they may slide thru the vagina and prolapse unopposed thru the hernia-prone opening(s) in the pelvis floor to the outside dragging the vagina (wall) with them as intussusception

the same as with fistulas whereby urine and/or stool will leak from the high-pressure bladder respectively high-pressure rectum first into the zero-pressure vagina and then further leak thru the vagina to the outside

the notion that the levator ani muscles play a major role in prevention, if intact and well functioning, and in mechanism of prolapse, if weak, cannot be confirmed

to the author it looks far-fetched since there is nowhere direct contact between these organs (wall) and the levator ani muscles; not even when herniated/prolapsed

consider the tube-like configuration of the pelvis space and all the different intrapelvic structures between the pelvis floor and the organs

by what mechanism would the action of the levator ani muscles contribute

the diameter recta between the underside of symphysis and tip of coccyx is 9-9.5 cm and the levator ani muscles are fused as levator plate at minimally 7 cm from symphysis and fixed to coccyx/anococcygeal ligament; and the distance from ischial spine to coccyx is minimally 5-6 cm

so at no point it is possible that the posterior union of the levator ani muscles can come into direct contact with the posterior bladder wall, the cervix, the intraperitoneal contents or the anterior rectum wall; by contraction or anything physiologic

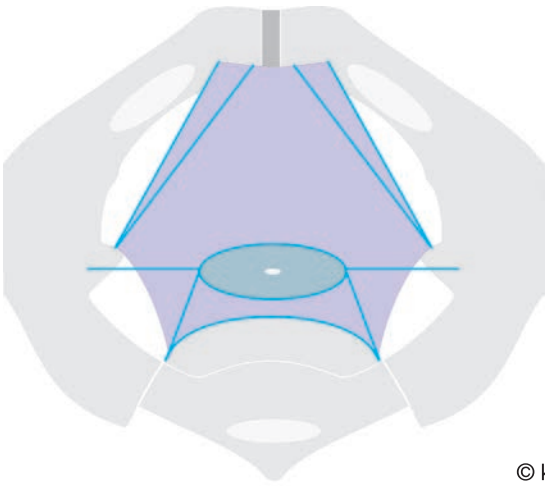
if there is no contact how can the levator muscles now prevent the development of defects within the fascia structures between the organs and the vagina

prolapse is not thru the levator ani muscles and other pelvis floor structures but the prolapse is thru defects in the intrapelvic urogenital diaphragm due to which and the bladder and/or cervix and/or intraperitoneal contents are no longer supported and start to descend/herniate

if there is herniation, the herniated organ will slide unopposed thru the vagina dragging the vagina (wall) with it and may prolapse to the outside

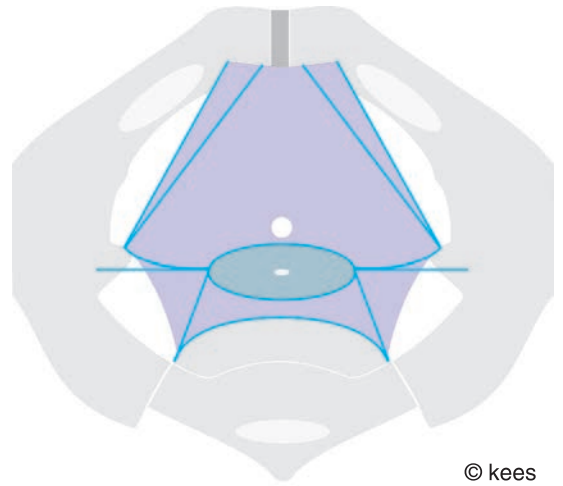
this process also cannot be prevented or stopped by the levator ani muscles or other pelvis floor structures, either relaxed or contracted

since the intrapelvic urogenital diaphragm is also supporting the female anatomic urine continence mechanism prolapse may be accompanied by urine incontinence if the defect results in loss of support



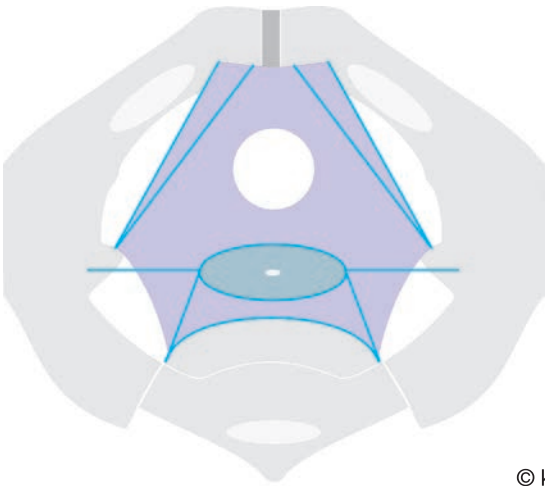
© kees

fig 135 intrapelvic urogenital diaphragm



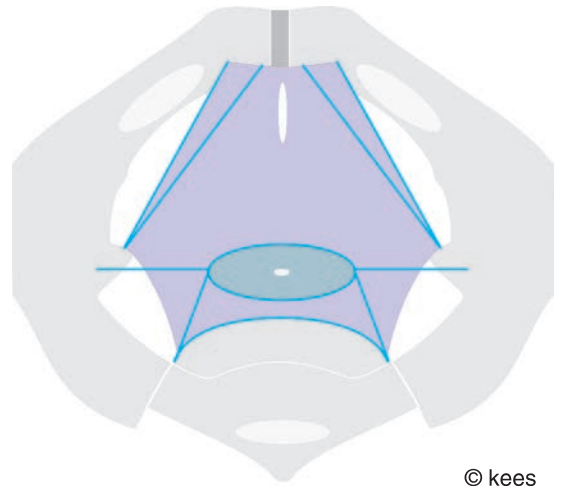
© kees

fig 136 small anterior trauma



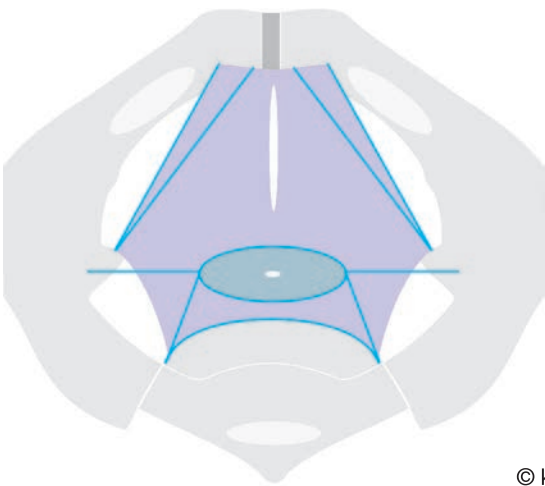
© kees

fig 137 large anterior trauma



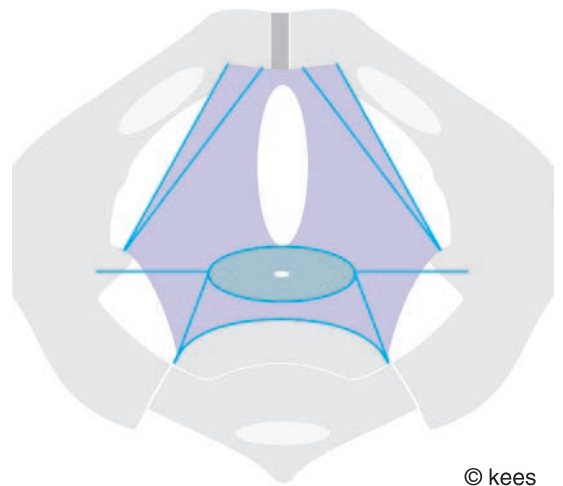
© kees

fig 138 longitudinal trauma



© kees

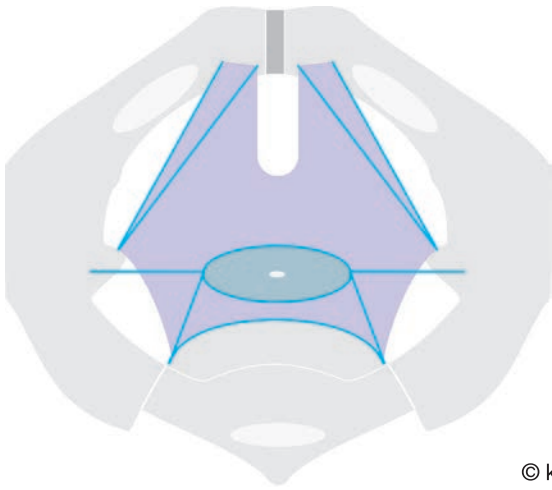
fig 139 longitudinal trauma



© kees

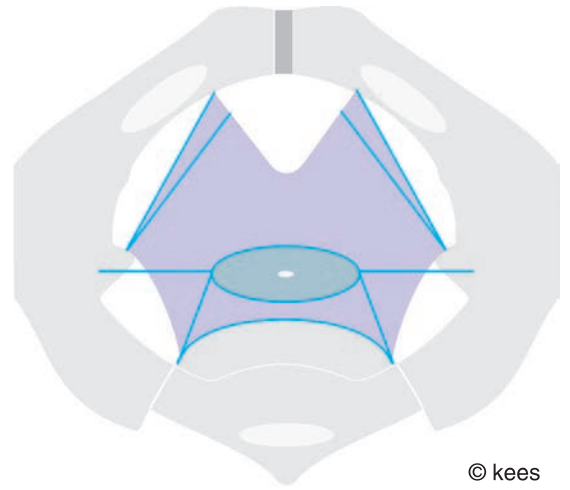
fig 140 large longitudinal trauma





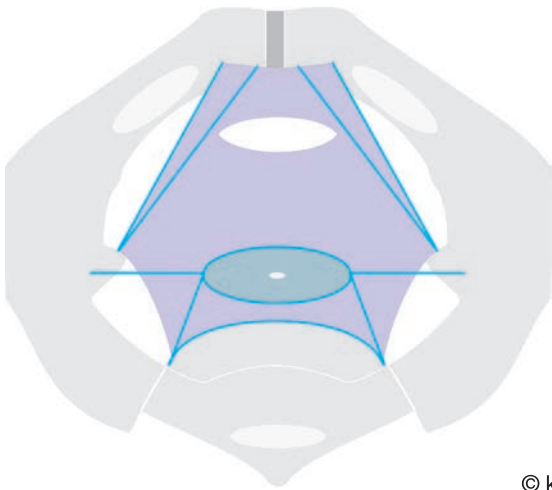
© kees

fig 141 anterior longitudinal median trauma



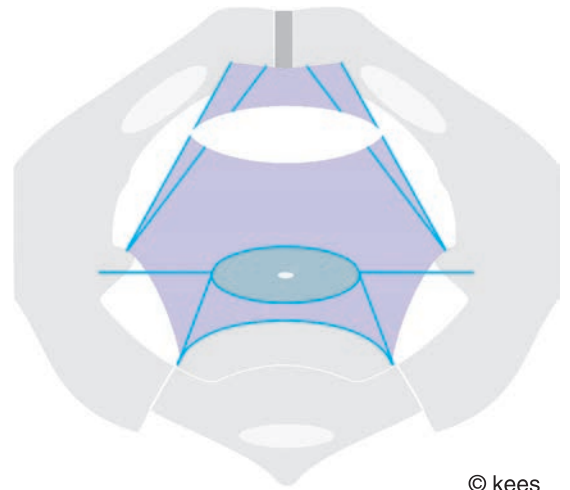
© kees

fig 142 anterior trauma atf/atlam loss



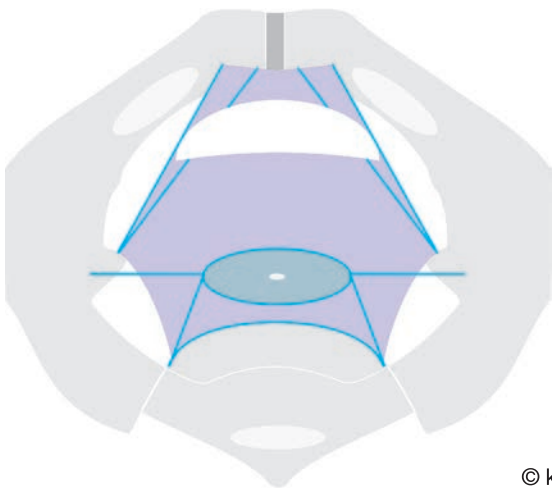
© kees

fig 143 transverse trauma



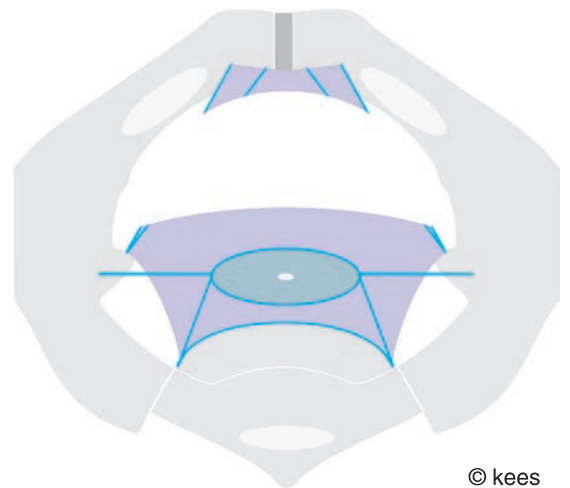
© kees

fig 144 transverse trauma atf/atlam loss



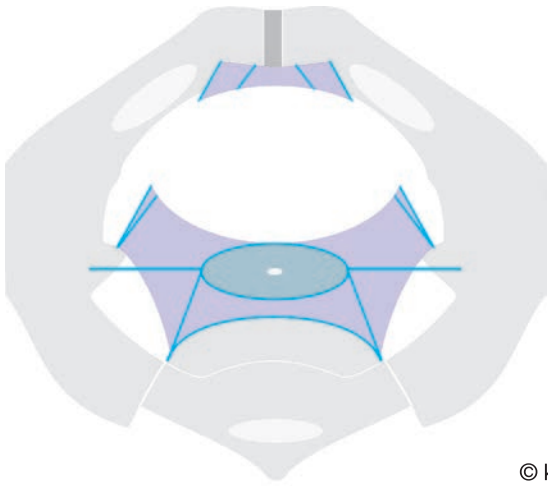
© kees

fig 145 quartercircular trauma



© kees

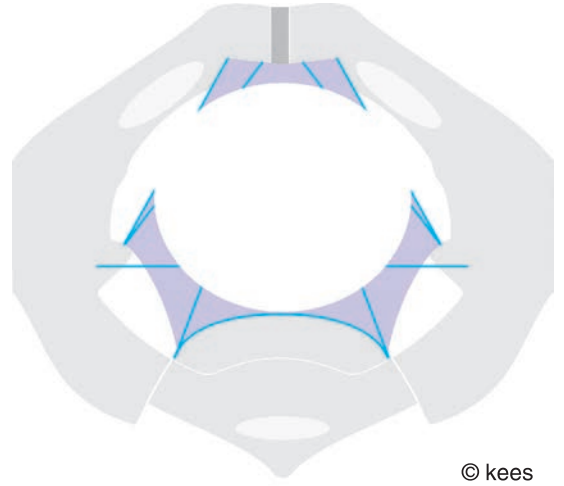
fig 146 semicircular trauma



© kees

fig 147

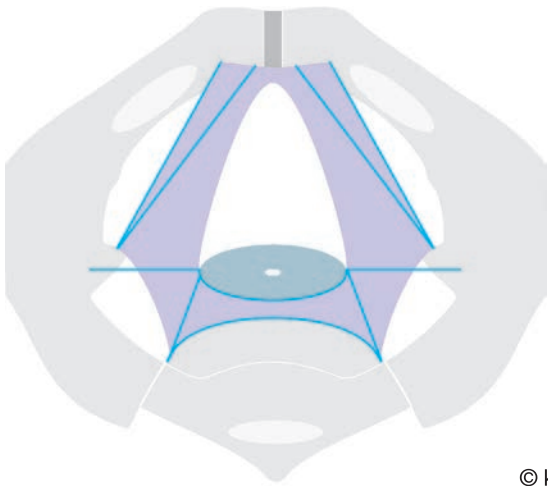
subtotal fascia loss



© kees

fig 148

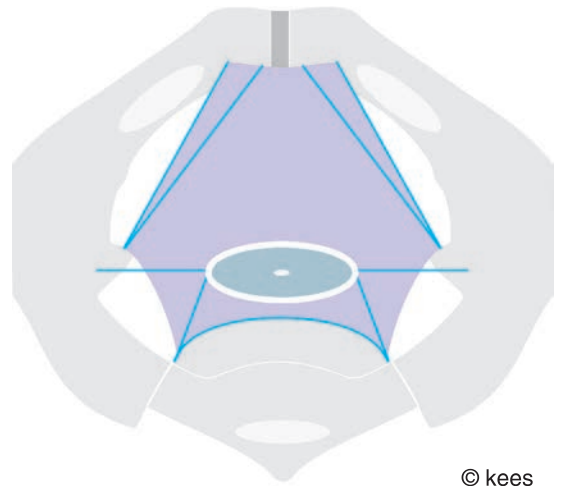
subtotal diaphragm loss



© kees

fig 149

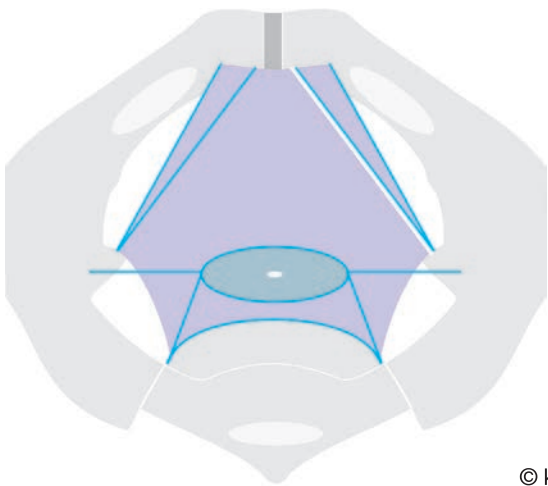
fascia trauma stress incontinence



© kees

fig 150

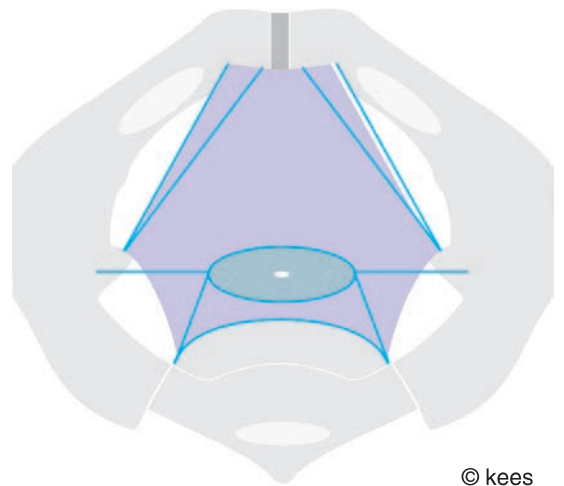
detachment cervix anchoring



© kees

fig 151

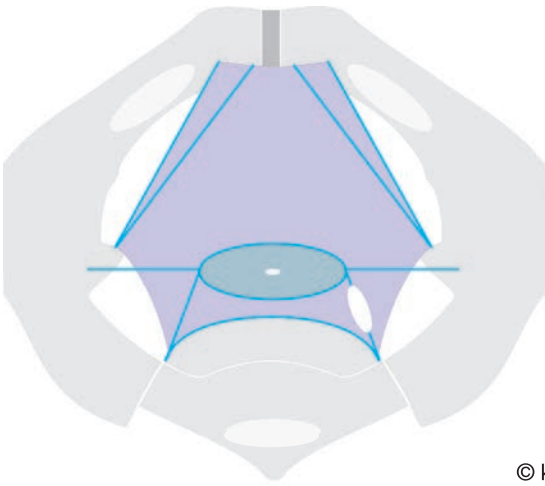
shearing at atf



© kees

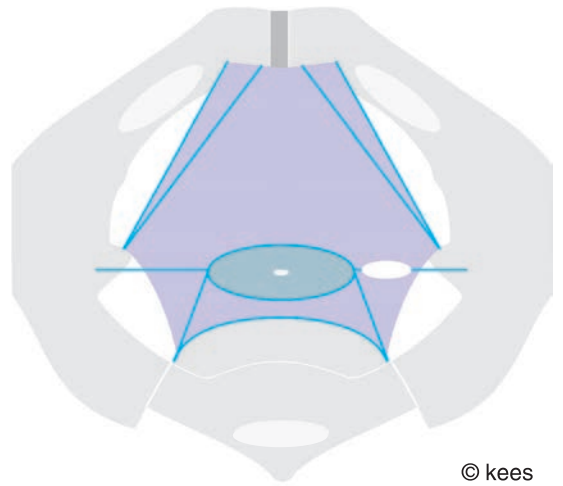
fig 152

shearing at atlam



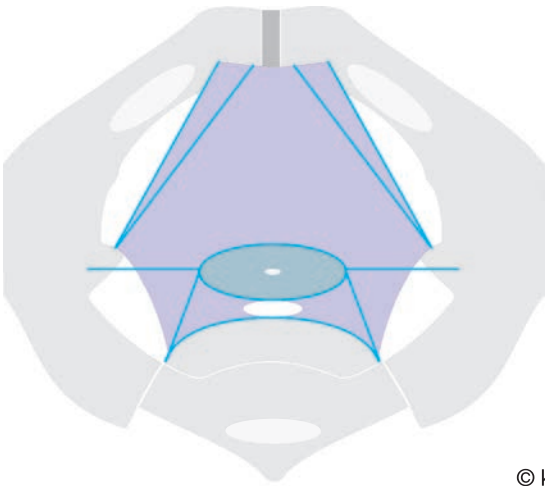
© kees

fig 153 trauma sacrotuberous ligament



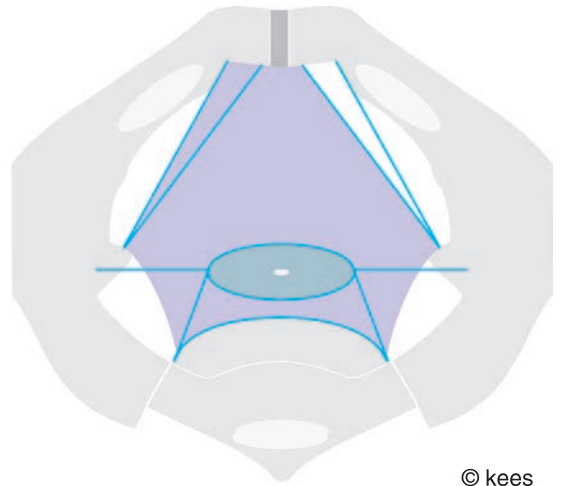
© kees

fig 154 trauma cardinal ligament



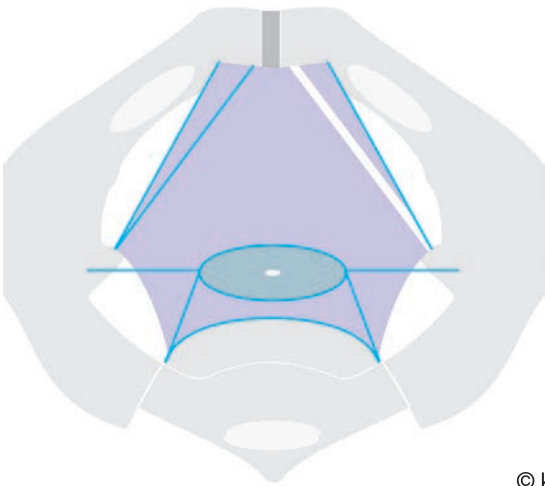
© kees

fig 155 fascia defect enterocele



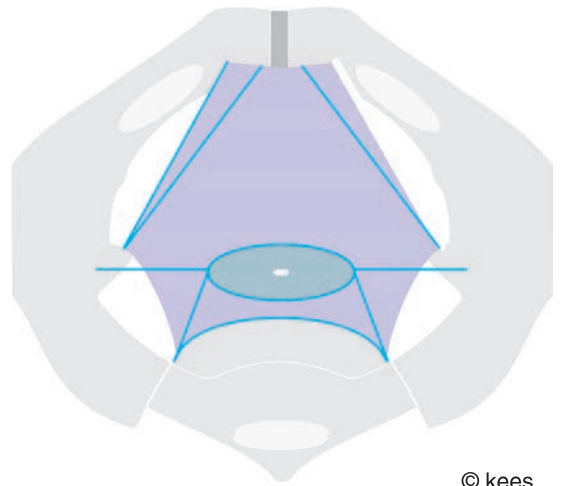
© kees

fig 156 total fascia sheath loss



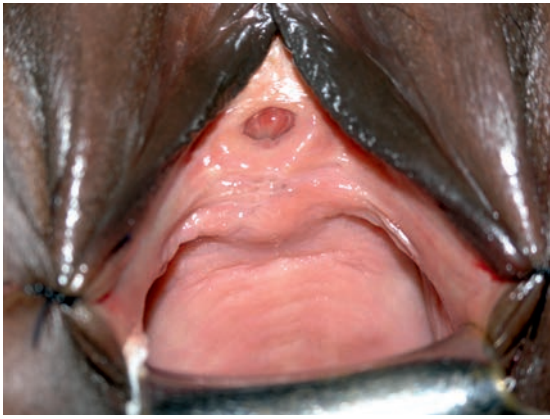© kees

fig 157 total atf loss



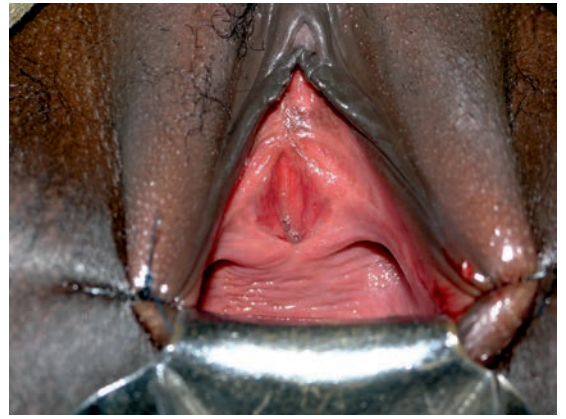© kees

fig 158 total atlam loss



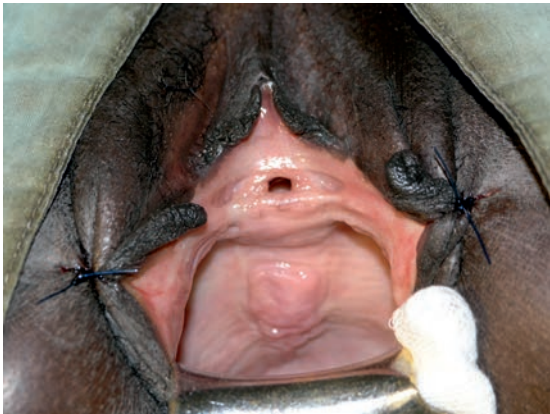© kees

fig 159 open euo



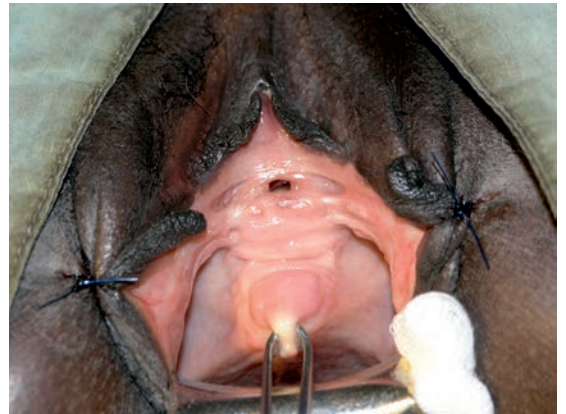© kees

fig 160 detachment euo anchoring



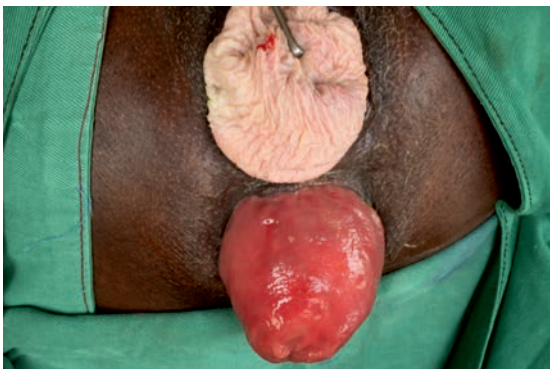© kees

fig 161 urethrocele



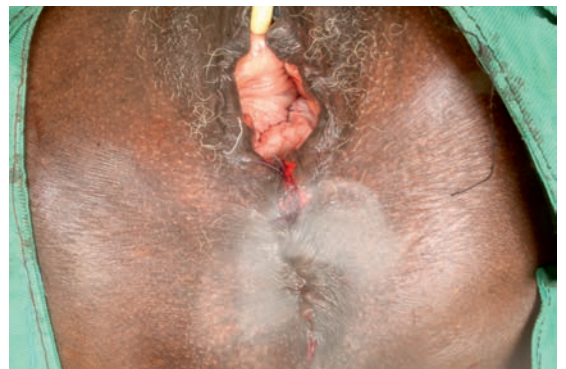© kees

fig 162 urethrocele



© kees

fig 163 total cervix prolapse  
rectum prolapse



© kees

fig 164 after repair

# functional pelvis anatomy

## essentials

### **true pelvis cavity**

a confined space for the distal outlet organs of the urinary tract anteriorly, the genital tract in the middle and the digestive tract posteriorly with hydrostatic and compression pressure; normally in a continent way and divided into

#### **pre\_subperitoneal cavity**

for the distal end parts of the urinary tract: pelvic ureters, bladder and urethra

#### **superitoneal subdiaphragmatic cavity**

for the distal end parts of the genital tract: cervix and vagina

#### **subperitoneal subseptal cavity**

for the distal end parts of the digestive tract: rectum, anorectum and sphincter ani

enclosed by

#### **parietal pelvis fascia**

and

#### **parietal peritoneum**

as connected to each other by

#### **tela urogenitalis**

### **corpus intrapelvinum as dynamic matrix**

connective tissue body of pelvis consists of a cohesive mixture of collagen for strength, elastin for passive elasticity and plasticity and mostly smooth muscle fibers for active non-fatigue tonus in a loose, dense or condensed form as

a dynamic matrix into which the organs and their supply are embedded and suspended/connected to the pelvis wall and each other by highly specialized structures

protecting the organs and their supply against trauma and stabilizing/securing them in their anatomic position

as coordinated by the autonomic nervous system

### **intrapelvic urogenital diaphragm**

highly specialized structure of corpus intrapelvinum from pubis bone bodies anteriorly to sacrum posteriorly as connected to bilateral arcus tendineus fasciae with cervix as centrum tendineum intrapelvinum since all fascia structures are connected to it

as first line of counteracting intraabdominal hydrostatic pressure and

supporting the urogenital continence mechanisms in their anatomic position and

preventing herniation of the urogenital tract and intraperitoneal contents into the zero-pressure vagina

### **pelvis floor as one functional unit**

levator ani muscles connected firmly to the perineum outlet diaphragm via perineal body and external sphincter ani muscle supporting and reinforcing each other

levator ani muscles as "pelvis diaphragm" highly overrated with direct action on stool continence mechanism and only indirect action on urine continence mechanism

perineum outlet diaphragm into which the end outlet organs with their striated sphincter mechanisms are anchored and supporting directly and the urine and stool continence mechanisms

**female urine continence mechanism** over in total 4-5 cm  
bladder neck, uv-junction and whole urethra  
supported by the intrapelvic urogenital diaphragm  
there is an internal smooth muscle sphincter and an external striated rhabdosphincter  
with washer effect by the mucosa and submucous vascular plexus  
continence potential over its whole length

**female genital continence mechanism** over in total 3-4 cm  
with cervix as internal smooth muscle sphincter as anchored into intrapelvic urogenital  
diaphragm

**female stool continence mechanism** over in total 4-5 cm  
anorectum and external sphincter ani  
anchored within perineum outlet diaphragm  
there is an internal smooth muscle sphincter and an external striated sphincter ani  
muscle with washer effect by mucosa and submucous vascular plexus

**urine stress incontinence mechanism** genuine and post fistula repair  
distortion of smooth muscle arrangement of the urethra with weakening of the intrinsic  
closing forces due to backward rotation/shifting of mobile posterior urethra wall away  
from the immobile anterior urethra wall  
by downward/caudad traction/push, by posterior traction towards sacrum due to defects  
within the support by the intrapelvic urogenital diaphragm and by defects within the  
anchoring into perineum outlet diaphragm; isolated or combined

**pelvis floor muscle exercises**  
have a positive effect upon the urine and continence mechanism since  
the perineum outlet diaphragm contributes to the urine and stool continence mechanism  
by further stabilizing the outlet parts  
the levator ani muscles contribute directly to the stool continence mechanism to which  
they are anatomically connected but only indirectly to the urine continence mechanism  
with no anatomic connection whatsoever  
with simultaneous reflex contraction of the external striated muscle sphincters

**obstetric trauma**  
due to hydrostatic pressure, dilatation of birth canal, (in)direct cutting thru, shearing and  
compression; and in prolonged obstructed labor due to pressure necrosis  
resulting in an enormous variety of defects from minimal to extensive

**urogenital and digestive prolapse**  
herniation of adjacent high(er)-pressure organs into the zero-pressure vagina and then  
further prolapse thru the vagina dragging vagina wall with them as intussusception  
due to defects within the separating and supporting fascia structures of the corpus intra  
pelvinum between these organs and the vagina  
levator ani muscles and perineum outlet diaphragm do not play a role in this process  
since there is no anatomic contact between those organs and these structures

**reconstructive surgery**  
the science is to identify the specific defects whilst the art is to reconstruct the functional  
anatomy using the available autologous structures

# **reconstructive surgery**

## what is needed before a start is made

one has to master the complicated anatomy of the pelvis, the pelvis organs and their supply as embedded within the corpus intrapelvinum and the pelvis floor

one has to understand the functional anatomy as interaction between the different structures in order

to understand the physiology of the anatomic urine and stool continence mechanisms in the female

one must be able to identify the individual structures of the functional anatomy in the living female; which is different from the postmortem dead anatomy

one has to study and understand the mechanism of action of the obstetric trauma, what it does to the functional anatomy of the individual structures and master the enormous variety of lesions

one must study, understand and master the mechanisms of action of urine and stool incontinence and of prolapse in the female

one must be able to identify and assess the individual obstetric trauma defects in the living female

then one must devise a plan of action how to reconstruct the functional anatomy as customized to the individual findings and needs

one must master the principles of general, gynecologic, urologic, colorectal and reconstructive surgery and since the vagina is never sterile also the principles of septic surgery

one must understand and respect the natural tissue forces inside the human body as to physiologic stress

one must master the physiologic healing processes in order to promote the enormous natural healing potential of the human body

preferably one undergoes a practical training with a step-by-step approach where the basic skills are demonstrated in order to learn these skills

though the skills can be demonstrated and be practiced step by step under strict supervision there is **NO** automatic transfer of these skills and the ultimate responsibility for any surgery rests upon the performing surgeon

the decisive factor in surgery is the surgeon

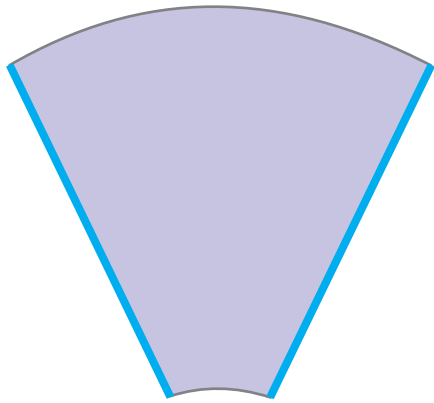


fig 165

pubocervical fascia

© kees

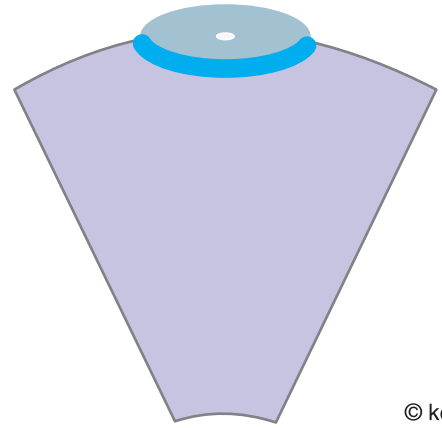


fig 166

anterior cervix fixation

© kees

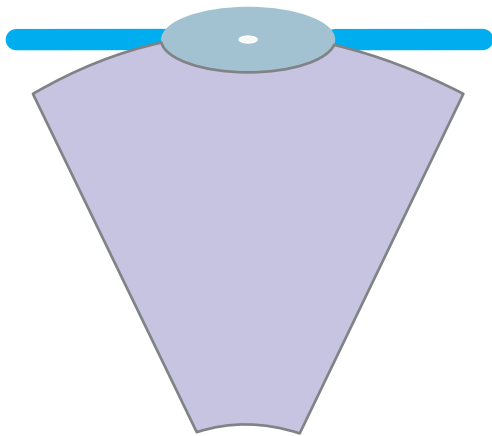


fig 167

lateral cervix fixation  
broad and cardinal ligaments

© kees

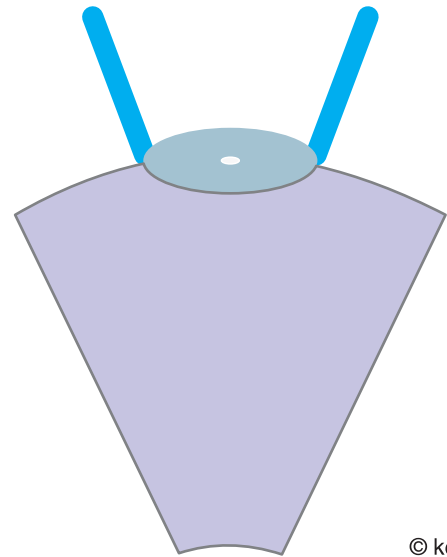


fig 168

posterior cervix fixation  
sacrouterine ligaments

© kees

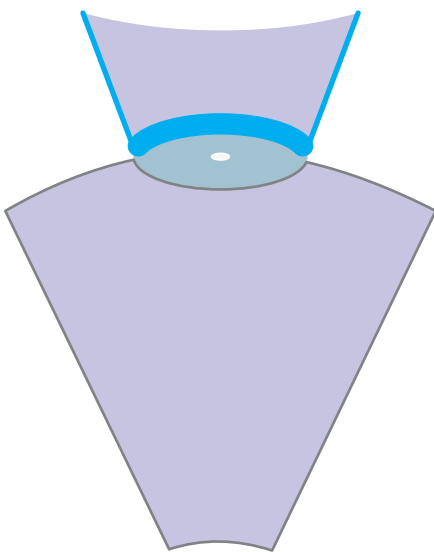


fig 169

posterior cervix fixation  
rectovaginal fascia

© kees

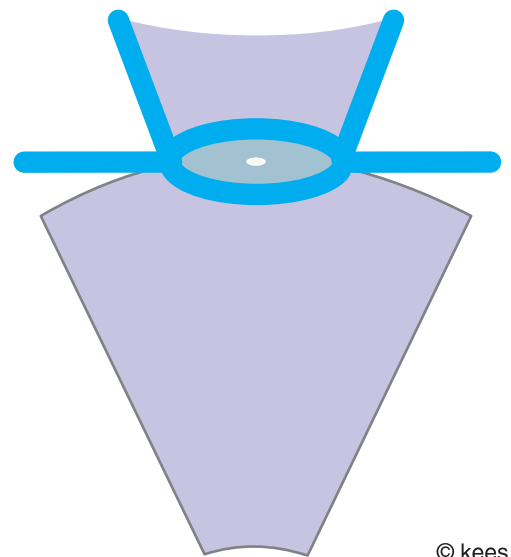
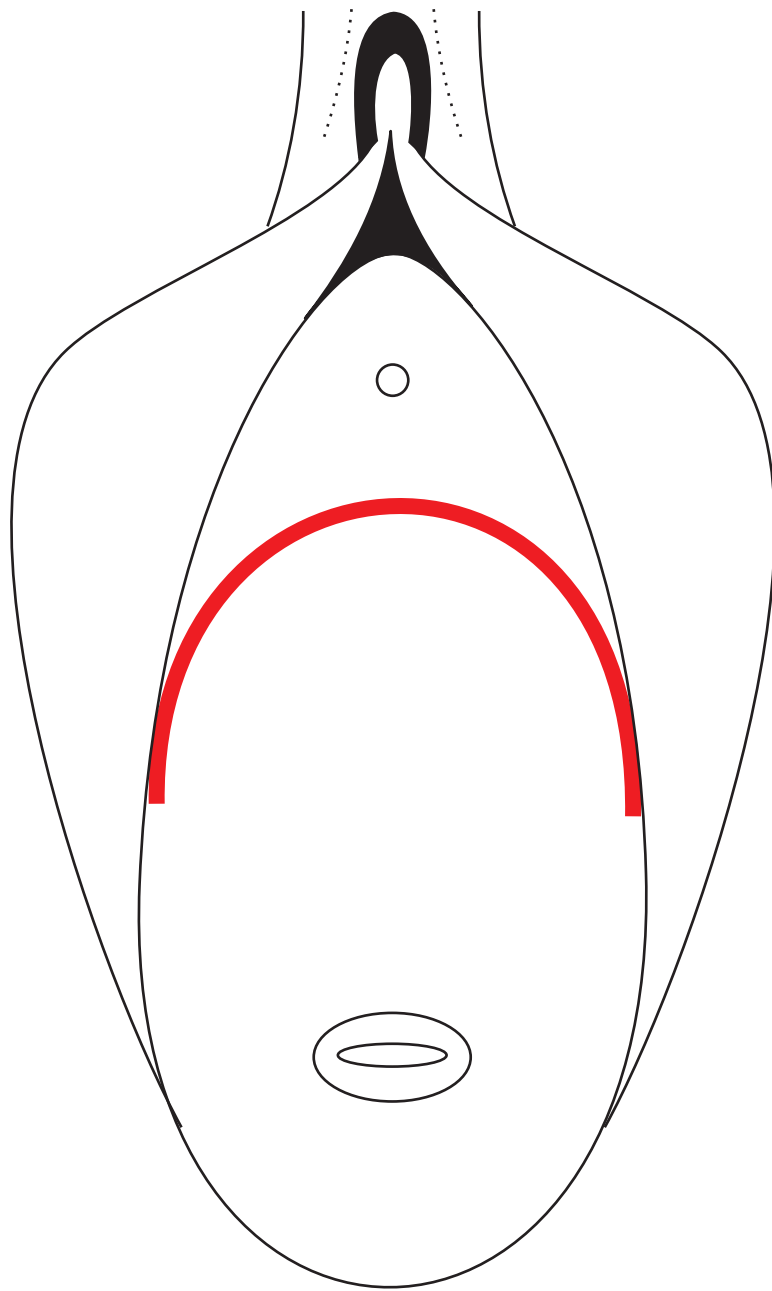


fig 170

total cervix fixation

© kees





© kees

physiologic incision  
anterior vagina wall

## references

- hafferl a  
lehrbuch der topographischen anatomie    springer verlag 1957
- gardner e, gray d j, o'rahilly r  
anatomy; a regional study of human structure    saunders 1975
- delancey j o l  
why do women have stress incontinence    neurourol urodyn 2010; 29:s13-s17
- ashton-miller j a and delancey j o l  
functional anatomy of the female pelvic anatomy    ann ny acad sci 2007; 1101: 266-296
- delancey jol and ashron-miller j a  
pathophysiology of adult urine incontinence    gastroenterology 2004; 126: 623-632
- barber d b  
contemporary views of female pelvic anatomy    cleveland clin j med 2005 vol 72 suppl 4 S3-S11
- lahodny j  
vaginale inkontinenz- und deszensuschirurgie    ferdinand enke verlag stuttgart 1991
- martius h  
die gynäkologischen operationen und ihre topographisch-anatomischen grundlagen  
georg thieme verlag 1960
- paul abrams, lindia cardozo, saad khoury, alan wein editors  
incontinence iucd 5th edition 2013, pp 1487-
- waaldijk k  
obstetric fistula surgery; art and science; the basics    printmarkt.eu 2008
- waaldijk k  
25,000 obstetric trauma procedures as covered by 30 annual evaluation reports
- waaldijk k  
obstetric trauma surgery; art and science; sphincter ani rupture    printmarkt.eu 2015

and as influenced by many others since the author started his medicine study in 1959 but especially by prof j m greep, prof t k a b eskes and dr med h stenkoff

printed by:



info@printmarkt.eu  
www.printmarkt.eu

